

Probable Anti-Glutamate Decarboxylase 65 (Gad65) Antibody-Associated Cerebellar Ataxia. Clinical Case Report and Literature Review

J. Valinčiūtė*
P. Petkevičiūtė*
R. Balnytė**
J. Čiauškaitė**

**Faculty of Medicine, Medical Academy, Lithuanian University of Health Sciences, Lithuania*

***Department of Neurology, Medical Academy, Lithuanian University of Health Sciences, Lithuania*

Summary. *Introduction.* As more information about cerebellar ataxia induced by anti-GAD65 antibodies is accumulated, cerebellar dysfunction is increasingly associated with autoimmune causes. The prevalence of other neurological syndromes associated with anti-GAD65 antibodies has been estimated, but the occurrence of cerebellar ataxia of the same cause has not yet been reported. The clinical presentation and management of anti-GAD65 antibodies induced cerebellar ataxia are currently known only from single cases and small series reports.

Case report. We present a clinical case of a 52-year-old woman who was admitted to the hospital due to dizziness, impaired coordination, occasional choking, and slurred speech. Diagnostic procedures were performed, in which anti-GAD65 antibodies and atrophic changes in the upper parts of the cerebellum were detected on brain MRI, which led to a possible diagnosis of anti-GAD65 antibody-associated cerebellar ataxia.

Discussion and literature review. Patients tend to be women in their 60s with clinical symptoms such as gait and posture ataxia. Most patients present with nystagmus, dysarthria, and limb ataxia. To make the diagnosis, it is crucial to detect high titers of anti-GAD65 antibodies, do intrathecal anti-GAD65 antibody synthesis, and perform a brain MRI, which may reveal atrophy of the cerebellum as the disease progresses. Corticosteroids are one of the recommended treatment methods, which were effective in our case. Maintenance therapy is essential to prevent relapse of the disease.

Keywords: anti-GAD65 antibody, cerebellar ataxia.

INTRODUCTION

Cerebellar dysfunction is increasingly associated with autoimmune causes. Recent studies provide an increasing amount of information on cerebellar ataxia (CA) induced by anti-glutamate decarboxylase 65 (GAD65) antibodies (Ab). Nevertheless, neurological syndromes as-

sociated with the latter antibodies are uncommon. The most frequent of these are limbic encephalitis (LE), stiff person syndrome (SPS), and refractory epilepsy. The prevalence of LE and SPS has been estimated [1], but the occurrence of cerebellar ataxia induced by anti-GAD65 antibodies has not yet been reported. The clinical presentation and management of this disease are currently known only from single cases and small series reports [2].

Therefore, we present a clinical case of a 52-year-old woman diagnosed with possible anti-GAD65 antibody-associated cerebellar ataxia. The patient's clinical symptoms progressed over time, and various diagnostic procedures were performed to confirm the final clinical diagnosis. This clinical case illustrates the slow progression and complexity of the disease, as well as the importance of comprehensive differentiation from other diseases.

Address:

*Justina Valinčiūtė
Department of Neurology, Medical Academy,
Lithuanian University of Health Sciences
Eiveniu Str. 2, LT-50009 Kaunas, Lithuania
E-mail: justina.valinciute@gmail.com*

© Neurologijos seminarai, 2023. Open Access. This article is distributed under the terms of the Creative Commons Attribution 4.0 International License CC-BY 4.0 (<http://creativecommons.org/licenses/by/4.0/>), which permits unrestricted use, distribution, and reproduction in any medium, provided you give appropriate credit to the original author(s) and the source, provide a link to the Creative Commons license, and indicate if changes were made.

CLINICAL CASE PRESENTATION

A 52-year-old woman was admitted to the Department of Neurology in 2022 due to complaints of increased dizziness, impaired coordination, occasional choking, and slurred speech. Medical history revealed the patient's comorbidities: arterial hypertension and depression. The patient denied allergies. The woman claimed to be taking salbutamol inhalations because of a previous COVID-19 infection, sertraline 100 mg once a day, agomelatine 50 mg once a day, clorazepate 5 mg twice a day, zolpidem 10 mg once in the evening, trazodone 50 mg once in the evening, and antihypertensive drugs.

The results of the analysis of previous medical data revealed that in 2018, the patient was admitted to a local hospital with similar symptoms, such as nausea, dizziness, and high blood pressure after waking up. The examination led to a vestibular neuronitis diagnosis. After receiving treatment, the patient's condition improved and she was discharged to continue treatment at home. However, in 2019, the symptoms recurred, and the patient was referred to an otoneurologist, who concluded that nystagmus was possibly due to damage to the central system. Moreover, brain magnetic resonance imaging (MRI) was performed but no significant changes were found.

Later in 2019, the patient's condition worsened, with weakness and coordination impairment of the right limbs and impaired walking (ataxic gait and requiring assistance), and she was referred to the Department of Neurology. Neurological examination revealed bilateral horizontal third-degree nystagmus and vertical nystagmus. According to the Lovett scale, the muscle strength of the right limbs was 4 points and of the left limbs was 5 points. Reflexes in the right arm were slightly stronger than in the left arm, and lower limb reflexes were stronger symmetrically. There was a tendency to the Babinski reflex on the right, weaker plantar reflex bilaterally. Finger-to-nose and heel-to-shin tests were performed, which showed ataxia of the right limbs. Movements were slow, gait was ataxic, and ataxia was observed more in the right limbs: while walking, the patient put the right leg higher. Also, a lower amplitude of physiological synkinesis was observed.

To exclude various causes of cerebellar ataxia, tests for vitamin B12 (possible deficiency), thyroid hormones: thyroid-stimulating hormone (TSH) and tetraiodothyronine (T4) (suspected hypothyroidism), as well as infectious disease markers (treponema pallidum hemagglutination assay (TPHA), human immunodeficiency virus 1 and 2 (HIV1/HIV2) and p24 antigens, IgM and IgG against *Borrelia burgdorferi*, IgM and IgG against tick-borne encephalitis), were performed. However, no changes were found: vitamin B12, TSH, and T4 were within normal range and infectious markers were negative, except for IgG against tick-borne encephalitis because of previous vaccination.

Autoimmune encephalitis was then suspected, and several tests were performed to exclude it. The brain MRI in

T2W/Flair mode showed single, nonspecific, hyperintense signals in the right frontal and parietal subcortical areas, possibly microangiopathic foci, without atrophic changes in the cerebellum (Fig. 1 and Fig. 3A). Analysis of the cerebrospinal fluid (CSF) showed: 0.4 g/L of total protein concentration, 3.55 mmol/L of glucose, 9×10^6 /L of white blood cells, no oligoclonal bands were found. Antibodies for paraneoplastic syndrome and autoantibodies against neuronal surface antigens were investigated. Only serum anti-GAD65 Ab were positive (1+). Electroencephalography (EEG) was performed and showed no changes. On suspicion of stiff person syndrome, electroneuromyography (ENMG) was performed and revealed no pathological changes. Furthermore, some diagnostic procedures were taken to exclude oncological processes: thyroid ultrasound, ultrasound of the upper abdomen, mammogram, faecal occult blood test, and chest X-ray. No significant deviations were observed. During hospitalization, the patient was treated with methylprednisolone 1 g once a day for 3 days. The patient's neurological status had not changed during the time of hospitalization, and the patient was discharged.

In 2022, the patient was again admitted to the Department of Neurology because of persistent symptoms. Additionally, occasional choking and slurred speech appeared. Neurological examination showed slurred and chanting speech, bilateral horizontal and vertical nystagmus, a tendency to the Babinski reflex on the right, and a positive Babinski reflex on the left. Finger-to-nose and heel-to-shin tests were performed with dysmetria, this time, especially on the left. The patient had an ataxic gait and needed assistance walking.

Several tests were repeated: for vitamin B12, TSH, and T4 and the same infectious markers for neurosyphilis, Lyme disease, tick-borne encephalitis, and HIV1/HIV2. All tests were negative, and there were no new findings. On suspicion of gluten ataxia, anti-Gliadin (GAF-3X) IgA and IgG, antibodies to tissue transglutaminase (anti-tTG) IgA and IgG were searched, but the results were negative. Wilson's disease was also considered, but the level of ceruloplasmin was only 0.33 g/L (normal range 0.22-0.58 g/L). MRI of the brain was repeated and showed, as before, non-specific, hyperintense signals, probably of microangiopathic origin, in the cerebral hemispheres in the T2W/Flair mode. New findings were also discovered: atrophic changes in the upper parts of the cerebellum (Fig. 2 and Fig. 3B).

A consultation with a clinical pharmacologist was requested about the medications the patient was taking to evaluate whether they might worsen the woman's condition. The clinical pharmacologist stated that abruptly stopping sertraline or using trazodone and clorazepate could cause ataxia as a side effect. However, no information on the abrupt discontinuation of sertraline was gathered, and the symptoms appeared before trazodone and clorazepate were administered. Blood tests and CSF analysis were performed again, showing no significant changes: total protein concentration 0.39 g/L, glucose 3.77 mmol/L,

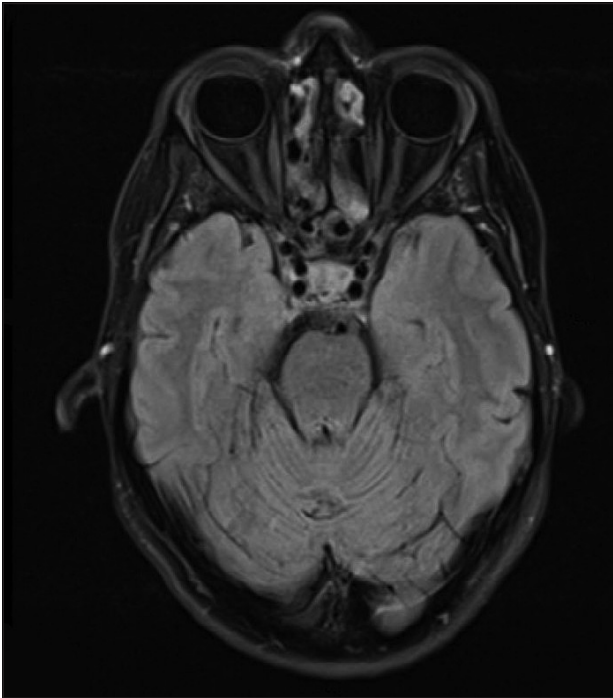


Fig. 1. Brain MRI in T2W/Flair mode (axial plane) shows no atrophic changes in the cerebellum.

oligoclonal bands not found. On the other hand, the crucial point was the rise in serum anti-GAD65 antibodies from 2019 (+1) to 2022 (+2). Moreover, the serum concentration of anti-GAD65 Ab detected by enzyme immunoassay was 2000 kU/L (normal values: 0-5 kU/L). On repeated investigation, where antibodies and cerebellar atrophic changes were found, and in the absence of any other cause that could explain the changes, anti-GAD65 antibody-as-

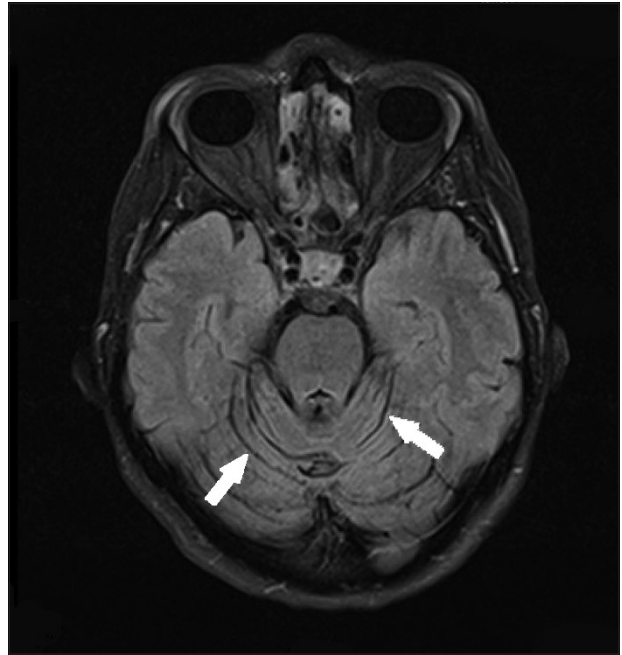


Fig. 2. Brain MRI in T2W/Flair mode (axial plane) shows atrophic changes in the cerebellum.

sociated cerebellar ataxia was considered the most likely cause. In this case, a definitive diagnosis could not be confirmed since this requires the detection of high titers of anti-GAD65 antibodies, which were not present in our case. Evidence of intrathecal synthesis of anti-GAD65 Ab and positive immunohistochemistry on brain tissue could also help confirm the diagnosis, however, this was not performed in this case.

During her stay in the Department of Neurology, the patient began pulse therapy with methylprednisolone 1 g

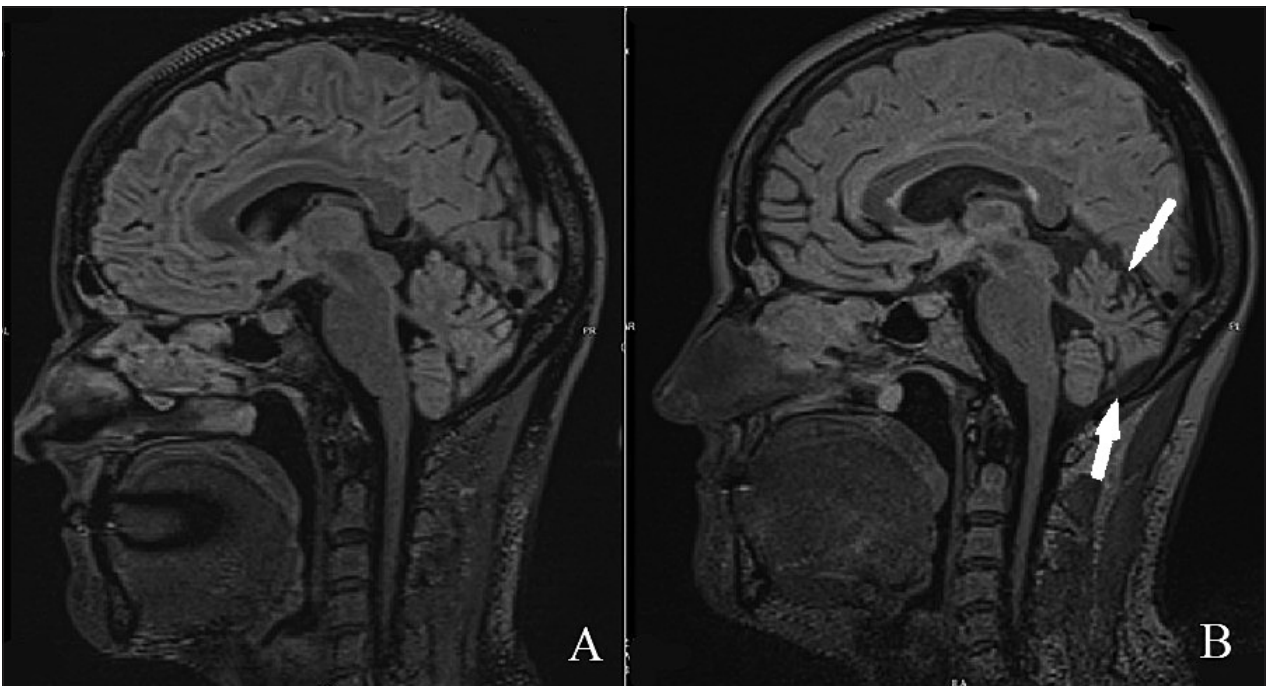


Fig. 3. Comparison of 2019 (A) and 2022 (B) brain MRI in T2W/Flair mode (sagittal plane) (show atrophic changes).

once a day for 5 days. The treatment was continued with prednisolone 60 mg per day for 7 days, reducing the dose to 50 mg per day and finally to 30 mg per day. During treatment, the patient's condition improved: tremors decreased, indicators on coordination tests improved. However, chanting speech and gait disturbance remained. The woman evaluated the improvement in her condition by 50%. Before discharge, the patient was assessed according to the International Cooperative Ataxia Rating Scale. The results were as follows: posture and gait score 27/34, kinetic score 25/52, dysarthria score 3/8, and oculomotor movement score 2/6. The total ataxia score was 54/100. The patient was recommended to continue using prednisolone 30 mg per day for 2-3 months, reducing the dose to 15 mg per day for 2 months, and referred to rehabilitation.

DISCUSSION AND LITERATURE REVIEW

Prevalence and pathogenetic mechanism of anti-GAD65 antibody-associated cerebellar ataxia

Anti-glutamate decarboxylase 65 antibody-associated cerebellar ataxia is a rare autoimmune neurological disorder. This condition most commonly occurs in women in their 60s, especially those with type 1 diabetes mellitus, autoimmune thyroid diseases, or other autoimmune disorders. Furthermore, about 70% of patients have serological evidence of gluten sensitivity [2-4]. However, in our case, the woman had no confirmed autoimmune disorders, but her age corresponded to the data in the literature. The patient was also tested for gluten sensitivity, but there was no serological evidence of this.

Glutamate decarboxylase (GAD) is mainly found in two locations: in pancreatic islet cells and CNS inhibitory (gamma-aminobutyric acid (GABA)-nergic) neurons. It exists as two isoforms: GAD65 and GAD67. GAD67 regulates the basal levels of GABA and is present in the cytoplasm of inhibitory neurons. GAD65 is responsible for GABA synthesis and exocytosis (transport of GABA into synaptic vesicles and control of synaptic release) [5, 6]. When anti-GAD65 antibodies are present in the organism, they approach GAD65 and interfere with GABA exocytosis. As a result, GABA levels decrease. Such disturbances can cause a deficit in cerebellar temporal coordination, which can lead to cerebellar ataxia [3]. In addition, a decrease in GABA levels affects an increase in the amount of glutamate. This leads to the activation of microglia and activation of the N-methyl-D-aspartate (NMDA) receptor, and then to the disruption of NMDA receptor-mediated responses. This causes dysfunctional signal transmission and finally cell degeneration. This is the main reason why cerebellar atrophy is noticeable in anti-GAD Ab-associated CA [5, 6]. Our clinical case also had visible atrophy, which took time to develop (about three years).

Clinical manifestation and diagnostics of anti-GAD65 antibody-associated cerebellar ataxia

Most patients have ataxia of gait and posture. Although 60 to 70% of patients have nystagmus, dysarthria, dysphagia, and limb ataxia. Usually, limb ataxia proceeds asymmetrically [2-4] (this was observed in our clinical case as well). Many exhibit mild ataxia and can walk unaided, but some may have severe or moderate ataxia and require a walking aid or a wheelchair [4]. Some patients may experience lumbar pain, muscle rigidity, and spasms, which can lead to frequent falls. Some patients may have drug-resistant focal epilepsy [2, 7]. In our clinical case, the patient experienced the symptoms mentioned in the literature, except for lumbar pain, muscle rigidity, spasms, and she did not suffer from drug-resistant focal epilepsy.

The onset of symptoms is subacute or chronic, progressing over months or years [1]. It is crucial to know the patient's complete medical history and perform a body assessment along with a neurological examination. It would be informative if patients with ataxia were assessed using the International Cooperative Ataxia Rating Scale. In our case, the patient was assessed on this scale only at the time of discharge in 2022, but it would be important to compare the results between 2019 and 2022 in order to monitor the progression of the disease over the years.

Blood tests to assess electrolytes and the analysis of CSF are also necessary. Occasionally, the oligoclonal bands may be present in the CSF [3]. However, in our case, CSF was performed twice (in 2019 and 2022), but no oligoclonal bands were found. Serum and CSF levels of anti-GAD65 antibodies are crucial for differential diagnosis since anti-GAD-Ab are found not only in patients with cerebellar ataxia but also in patients with other neurological diseases. Most often, the symptoms overlap with limbic encephalitis, stiff person syndrome, progressive encephalomyelitis with rigidity and myoclonus, and refractory epilepsy, which makes accurate clinical diagnosis difficult [5, 8]. This is the reason our patient underwent various diagnostic procedures, such as brain MRI, analysis of CSF, search for antibodies against neuronal surface antigens and against intracellular antigens, EEG, and ENMG to exclude other neurological diseases. However, only patients with anti-GAD65 cerebellar ataxia have high titers of these antibodies, usually more than 10,000 U/mL (or 10-100 times higher) [2, 5, 6, 9]. Furthermore, cerebellar vermian or hemispheric atrophy may be present on brain MRI, but the degree of atrophy is usually milder compared to the severity of ataxia [3, 4]. In our case, elevated serum anti-GAD65 antibody titers (2000 kU/L (normal values: 0-5 kU/L)), an increase in serum antibodies from +1 in 2019 to +2 in 2022, the dynamics of brain MRI from 2019 to 2022, when visible cerebellar atrophy appeared, and the exclusion of other causes of cerebellar ataxia (vitamin B12 deficiency, hypothyroidism, gluten ataxia, neurosyphilis, Lyme disease, tick-borne encephalitis, and other infectious diseases) led to the diagnosis of probable anti-GAD65 antibody-associated cerebellar ataxia. However, we cannot confirm a de-

finitive diagnosis, as in this case, not only were symptoms of cerebellar dysfunction present (dysphagia and pathological reflexes were observed in the patient), moreover, the anti-GAD65 titers were also not as high as indicated in the literature, and the changes observed on brain MRI were not inflammatory, but atrophic. Graus F et al. recommend that syndromes such as CA, which can be caused by various other mechanisms and etiologies, should be confirmed when there are high levels of anti-GAD65 antibodies in the CSF and these antibodies are synthesized intrathecally. Conditions without intrathecal anti-GAD65 Ab synthesis should be considered as ‘probably autoimmune’ [10]. Positive immunohistochemistry on the brain tissue may be also helpful to confirm the diagnosis [11].

An example to take into account is a retrospective study (conducted in 2020) of 56 patients with positive anti-GAD65 antibodies who were tested and divided into two groups: low concentration (n=20) of anti-GAD65 Ab and high concentration (n=36), where the cutoff value was 10,000 IU/mL in serum by automated quantitative ELISA. It was found, that high concentrations of antibodies were associated with classical anti-GAD65 syndromes (94%), such as cerebellar ataxia, chronic epilepsy, stiff-person syndrome, and other. However, in 12 patients with low concentrations of these antibodies, the clinical picture was present due to other causes, such as limbic encephalitis with anti-GABABR and pancreatic adenocarcinoma, various subacute and chronic polyradiculoneuropathies, and other non-immune mediated diseases such as multiple system atrophy and etc. These diseases were not related to the detection of anti-GAD65 Ab. The other 8 patients with low anti-GAD65 Ab had nonspecific ataxia and gait disorder or chronic epilepsy, but the association with anti-GAD65 antibodies in these patients was not determined [12]. This study confirms that low titers of anti-GAD65 are not always associated with autoimmune neurological disorders such as CA, which may also be possible in our case.

Management of anti-GAD65 antibody-associated cerebellar ataxia

First-line immunotherapy is used until remission. Immunotherapy begins with high doses of intravenous corticosteroids, intravenous immunoglobulin (IVIG), plasmapheresis, or rituximab. Depending on the situation, monotherapy or a combination of treatment methods can be chosen [6, 9, 13]. Some clinical cases have reported good outcomes with IVIG [14] or corticosteroids [15, 16] as first-line immunotherapy. Combinations can be various. A good example of combination therapy is IVIG and rituximab, which have shown great results [17]. The response to immunotherapy depends on the clinical course. In the subacute type, the response to combination therapy is higher than in the chronic type [13]. Maintenance therapy is usually needed. It consists of oral corticosteroids, IVIG, azathioprine, or mycophenolate mofetil [2, 16]. Good outcomes with the use of intravenous and oral corticosteroids were also observed in our case. Although

during the first hospitalization in the Department of Neurology, no response to intravenous immunotherapy was observed, after the last hospitalization and immunotherapy the patient’s condition improved: tremors decreased and indicators of coordination tests improved. At the beginning of the last hospitalization, the treatment with methylprednisolone pulse therapy was started and discontinued after 5 days, leaving the patient on oral prednisolone maintenance therapy for several months.

Anti-GAD titers should be monitored after each immunotherapy treatment to follow the clinical course. Long-term follow-up results show that immunotherapy improved CA in patients with the subacute type. A study involving 25 patients with anti-GAD65 Ab-associated CA showed that after immunotherapy, 35% of patients experienced an improvement of at least 1 point on the modified Rankin Score (mRS). Unfortunately, the CA progressed in patients, who had chronic type of CA and who did not receive immunotherapy [2].

Despite the treatment, the disease can relapse. Patients with chronic CA have more relapses than those with subacute CA. It is crucial to diagnose the disease at an early stage and to administer immunotherapy to improve the clinical course [2, 13, 18]. Patients younger than 60 years with a subacute clinical course and without cerebellar atrophy have overall better outcomes [19].

References

1. Dade M, Berzero G, Izquierdo C, Giry M, Benazra M, Delattre JY, et al. Neurological syndromes associated with anti-GAD antibodies. *Int J Mol Sci* 2020; 21(10): 3701. <https://doi.org/10.3390/ijms21103701>
2. Ariño H, Gresa-Arribas N, Blanco Y, Martínez-Hernández E, Sabater L, Petit-Pedrol M, et al. Cerebellar ataxia and glutamic acid decarboxylase antibodies: immunologic profile and long-term effect of immunotherapy. *JAMA Neurol* 2014; 71(8): 1009–16. <https://doi.org/10.1001/jamaneurol.2014.1011>
3. Mitoma H, Manto M, Hampe CS. Immune-mediated cerebellar ataxias: practical guidelines and therapeutic challenges. *Curr Neuroparmacol* 2019; 17: 33–58. <https://doi.org/10.2174/1570159X16666180917105033>
4. Hadjivassiliou M, Sarrigiannis PG, Shanmugarajah PD, Sanders DS, Grünewald RA, Zis P, et al. Clinical characteristics and management of 50 patients with anti-GAD ataxia: gluten-free diet has a major impact. *Cerebellum* 2021; 20(2): 179–85. <https://doi.org/10.1007/s12311-020-01203-w>
5. Mitoma H, Adhikari K, Aeschlimann D, Chattopadhyay P, Hadjivassiliou M, Hampe CS, et al. Consensus paper: neuroimmune mechanisms of cerebellar ataxias. *Cerebellum* 2016; 15(2): 213–32. <https://doi.org/10.1007/s12311-015-0664-x>
6. Mitoma H, Manto M, Hampe CS. Pathogenic roles of glutamic acid decarboxylase 65 autoantibodies in cerebellar ataxias. *J Immunol Res* 2017; 2017: 2913297. <https://doi.org/10.1155/2017/2913297>
7. Baizabal-Carvallo JF. The neurological syndromes associated with glutamic acid decarboxylase antibodies.

- J Autoimmun 2019; 101: 35–47. <https://doi.org/10.1016/j.jaut.2019.04.007>
8. Budhram A, Sechi E, Flanagan EP, Dubey D, Zekeridou A, Shah SS, et al. Clinical spectrum of high-titre GAD65 antibodies. *J Neurol Neurosurg Psychiatry* 2021; 92(6): 645–54. <https://doi.org/10.1136/jnnp-2020-325275>
 9. Mitoma H, Manto M, Hadjivassiliou M. Immune-mediated cerebellar ataxias: clinical diagnosis and treatment based on immunological and physiological mechanisms. *J Mov Disord* 2021; 14(1): 10–28. <https://doi.org/10.14802/jmd.20040>
 10. Graus F, Saiz A, Dalmau J. GAD antibodies in neurological disorders – insights and challenges. *Nat Rev Neurol* 2020; 16(7): 353–65. <https://doi.org/10.1038/s41582-020-0359-x>
 11. Daif A, Lukas RV, Issa NP, Javed A, VanHaerents S, Reder AT, et al. Antiglutamic acid decarboxylase 65 (GAD65) antibody-associated epilepsy. *Epilepsy Behav* 2018; 80: 331–6. <https://doi.org/10.1016/j.yebeh.2018.01.021>
 12. Muñoz-Lopetegui A, de Bruijn MAAM, Boukhrissi S, Bastiaansen AEM, Nagtzaam MMP, Hulsboom ESP, et al. Neurologic syndromes related to anti-GAD65: clinical and serologic response to treatment. *Neurol Neuroimmunol Neuroinflamm* 2020; 7(3): e696. <https://doi.org/10.1212/NXI.0000000000000696>
 13. Mitoma H, Hadjivassiliou M, Honnorat J. Guidelines for treatment of immune-mediated cerebellar ataxias. *Cerebellum Ataxias* 2015; 2(1): 14. <https://doi.org/10.1186/s40673-015-0034-y>
 14. Pedroso JL, Braga-Neto P, Dutra LA, Barsottini OGP. Cerebellar ataxia associated to anti-glutamic acid decarboxylase autoantibody (anti-GAD): partial improvement with intravenous immunoglobulin therapy. *Arq Neuropsiquiatr* 2011; 69(6): 993. <https://doi.org/10.1590/S0004-282X2011000700030>
 15. Lauria G, Pareyson D, Pitzolu MG, Bazzigaluppi E. Excellent response to steroid treatment in anti-GAD cerebellar ataxia. *Lancet Neurol* 2003; 2(10): 634–5. [https://doi.org/10.1016/S1474-4422\(03\)00534-9](https://doi.org/10.1016/S1474-4422(03)00534-9)
 16. McFarland NR, Login IS, Vernon S, Burns TM. Improvement with corticosteroids and azathioprine in GAD65-associated cerebellar ataxia. *Neurology* 2006; 67(7): 1308–9. <https://doi.org/10.1212/01.wnl.0000238389.83574.be>
 17. Planche V, Marques A, Ulla M, Ruivard M, Durif F. Intravenous immunoglobulin and rituximab for cerebellar ataxia with glutamic acid decarboxylase autoantibodies. *Cerebellum* 2014; 13(3): 318–22. <https://doi.org/10.1007/s12311-013-0534-3>
 18. Wiels W, Guisset F, Vandervorst F, Peeters I, Seynaeve L, Costa O, et al. Rapidly progressive cerebellar hemiataxia with high levels of GAD65 reactive antibodies. *Mov Disord Clin Pract* 2017; 4(4): 632–4. <https://doi.org/10.1002/mdc3.12504>
 19. Manto M, Mitoma H, Hampe CS. Anti-GAD antibodies and the cerebellum: where do we stand? *Cerebellum* 2019; 18(2): 153–6. <https://doi.org/10.1007/s12311-018-0986-6>
- J. Valinčiūtė, P. Petkevičiūtė, R. Balnytė, J. Čiauškaitė**
- TIKĖTINA ANTIKŪNŲ PRIEŠ GLUTAMO RŪGŠTIES DEKARBOKSILAZĘ 65 SUKELTA SMEGENĖLIŲ ATAKSIJA: KLINIKINIS ATVEJIS IR LITERATŪROS APŽVALGA**
- Santrauka**
- Įvadas.* Smegenėlių funkcijos sutrikimai vis dažniau siejami su autoimuninėmis priežastimis. Kartu didėja informacijos apie antikūnų prieš glutamo rūgšties dekarboksilazę 65 (anti-GAD65) sukeltą smegenėlių ataksiją kiekis. Šiuo metu apskaičiuotas kitų neurologinių sindromų, susijusių su anti-GAD65 antikūnais, paplitimas, tačiau apie tos pačios priežasties sukeltos smegenėlių ataksijos paplitimą dar nėra tikslų duomenų. Taigi anti-GAD65 antikūnų sukeltos smegenėlių ataksijos klinika ir gydymas šiuo metu žinomi tik iš pavienių klinikinių atvejų.
- Atvejo aprašymas.* Pristatomas klinikinis atvejis apie 52 metų amžiaus moterį, kuri buvo hospitalizuota dėl galvos svaigimo, sutrikusios koordinacijos, pasikartojančių springimo epizodų, nerišlios kalbos. Buvo atlikti diagnostiniai tyrimai, kurių metu rastas padidėjęs anti-GAD65 antikūnų titras ir smegenų MRT tyrime matomi atrofiniai pokyčiai viršutinėse smegenėlių dalyse leido įtarti galimą anti-GAD65 antikūnų sukeltos smegenėlių ataksijos diagnozę.
- Diskusija ir literatūros apžvalga.* Dauguma šia liga sergančių pacientų yra 60 metų amžiaus moterys, turinčios ataksinę eiseną ir laikyseną. Dažniausiai pacientams pasireiškia nistagmas, dizartrijs ir galūnių ataksija. Norint diagnozuoti ligą, labai svarbu nustatyti labai padidėjusį anti-GAD65 antikūnų tūrą, atlikti intratekalinę šių antikūnų sintezę ir smegenų MRT tyrimą, kuriame galima stebėti smegenėlių atrofiją, ypač ilgainiui ligai progresuojant. Rekomenduojama skirti kortikosteroidus, kurių skyrimas, mūsų pacientės atveju, buvo veiksmingas. Norint išvengti ligos atkryčio, itin svarbu skirti palaikomąją terapiją.
- Raktažodžiai:** anti-GAD65 antikūnai, smegenėlių ataksija.
- Gauta: 2022 10 06
Priimta spaudai: 2023 04 12