

Perforated peptic ulcer in children: diagnosis and treatment

Vaikų perforavusių skrandžio ir dvylikapirštės žarnos opų diagnostika ir gydymas

Jūratė Baltrūnaitė¹, Kęstutis Trainavičius²

¹ *Vilnius University, Faculty of Medicine, M. K. Čiurlionio Str. 21, LT-03101 Vilnius, Lithuania*

² *Children's Surgery Centre, Children's Hospital, Affiliate of Vilnius University Hospital Santariskiu Klinikos, Santariskiu Str. 7, LT-08406 Vilnius, Lithuania*

E-mail: Jurate.Baltrunaite@mf.stud.vu.lt

¹ *Vilniaus universiteto Medicinos fakultetas, M. K. Čiurlionio g. 21, LT-03101 Vilnius, Lietuva*

² *Vilniaus universiteto ligoninė Santariskių klinikos, Vaikų chirurgijos centras, Santariskių g. 7, LT-08406 Vilnius, Lietuva*

El. paštas: Jurate.Baltrunaite@mf.stud.vu.lt

Objectives

Perforated peptic ulcer (PPU) is a rare but life-threatening surgical emergency in childhood. The aim of our study was to analyse the clinical features, diagnosis and management of PPU in children.

Methods

The data of children diagnosed with gastroduodenal PPU at Children's Surgery Department, Children's Hospital, Affiliate of Vilnius University Hospital Santariskiu Klinikos from 1994 to 2012 were reviewed. The patients' age, sex, anamnesis, clinical features, examination results, operative findings and methods, medication therapy and outcomes were assessed. Statistical analysis was performed using MS Excel.

Results

There were 14 (93.3%) males and one female aged 14 to 18 years (16.3 ± 1.3) included in the study. Twelve patients (80%) were diagnosed with gastric and 3 (20%) with duodenal PPU. Eleven patients (73.3%) had dyspepsia before PPU, of them 4 had a history of peptic ulcer disease. Most patients (46.6%) arrived to the hospital within 6 hours of symptom onset. All presented with severe epigastric pain, 8 (53.3%) with nausea and vomiting. Only one patient (6.6%) complained of melena. One (6.6%) suffered from epigastric pain radiating to the left shoulder. Physical examination revealed positive peritoneal signs in 13 patients (86.6%). Subdiaphragmatic free air was detected in 12 patients (80%). The mean duration of perforation was 34.47 ± 57.41 hours (2-178). Thirteen patients (86.6%) underwent laparotomy, 2 laparoscopic repair. The anterior wall of the prepyloric gastric region was the commonest perforation site (80%). Eight patients (53.4%) had a course of *H. pylori* eradication therapy. The average hospital stay was 10.6 ± 6.3 days (4-32). Fourteen patients (93.3%) had an uneventful postoperative period, one developed nephrotic range proteinuria. All recovered fully.

Conclusions

Gastroduodenal PPU should be suspected in adolescent boys with a sudden onset of severe abdominal pain, positive peritoneal signs, and confirmed by pneumoperitoneum in the plain X-ray. Simple closure and eradication of *H. pylori* (when infection confirmed) are mandatory for a complete recovery.

Key words: gastric ulcer, duodenal ulcer, perforated peptic ulcer, children

Darbo tikslas

Skrandžio ar dvylikapirštės žarnos opos perforacija yra reta, tačiau gyvybei pavojinga vaikų būklė. Darbo tikslas – išanalizuoti vaikų perforavusių skrandžio ir dvylikapirštės žarnos opų kliniką, diagnostiką ir gydymą.

Tyrimo medžiaga ir metodai

Atlikta retrospektyvi ligonių, 1994–2012 m. gydytų Vaikų ligininės VUL SK filialo Vaikų chirurgijos skyriuje, duomenų analizė. Vertinta ligonių amžius, lytis, anamnezė, klinika, fizinio ir instrumentinio ištyrimo duomenys, operacijos radiniai, metodai ir trukmė, medikamentinė terapija ir ankstyvosios komplikacijos. Statistinė duomenų analizė atlikta *MS Excel* programa.

Rezultatai

Buvo tirta 15 vaikų: 14 (93,3 %) berniukų ir 1 (6,6 %) mergaitė. Vidutinis ligonių amžius buvo $16,3 \pm 1,3$ metų. Dvylikai (80 %) ligonių diagnozuota skrandžio, 3 (20 %) – dvylikapirštės žarnos opos perforacija. Iki perforacijos pilvo skausmais skundėsi 11 (73,3 %) ligonių, iš jų keturiems buvo diagnozuota opaligė. Dauguma ligonių (46,6 %) atvyko į liginę per 6 valandas nuo simptomų pradžios. Visi vaikai skundėsi labai stipriu skausmu pakrūtinio srityje, 8 (53,3 %) – pykinimu ir vėmimu. Tik 1 (6,6 %) vaikui buvo melena. Vienas (6,6 %) skundėsi pakrūtinio skausmu, plintančiu į kairį petį. 86,6 % tiriamųjų nustatyti pilvaplėvės dirginimo požymiai. Apžvalginėje pilvo rentgenogramoje 12 (80 %) ligonių rasta laisvo oro po diafragma. Ligoniai iki operacijos vidutiniškai sirgo $34,47 \pm 57,41$ valandas (nuo 2 iki 178). Laparotomija buvo atlikta 13 (86,6 %) ligonių, laparoskopija – 2 (20 %). Net 12 (80 %) vaikų perforavusios opos rastos skrandžio prepiliorinės dalies priekinėje sienoje. Aštuoniems ligoniams (53,4 %) skirta *H. pylori* eradikacinė terapija. Vaikai liginėje gydyti vidutiniškai $10,6 \pm 6,3$ dienas (nuo 4 iki 32). Pooperacinė eiga buvo sklandi 14 (93,3 %) ligonių, 1 (6,6 %) vaikui nustatyta nefrozinio lygio proteinurija. Visi ligoniai pasveiko.

Išvados

Skrandžio ir dvylikapirštės žarnos opos turėtų būti įtariamos paaugliams berniukams, kurie kreipiasi dėl ūminių stiprių pakrūtinio skausmų ir kuriems nustatytas pilvaplėvės dirginimas. Laisvas oras po diafragma apžvalginėje pilvo rentgenogramoje – itin svarbus požymis diagnozuojant ligą. Ulcerorafija ir *H. pylori* eradikacija (kai infekcija patvirtinta) yra būtini, kad pacientas visiškai pasveiktų.

Reikšminiai žodžiai: skrandžio opa, dvylikapirštės žarnos opa, perforavusi peptinė opa, vaikai

Introduction

Although peptic ulcer disease (PUD) is a known cause of paediatric abdominal pain, it is still an uncommon or at least not prevalent disorder among children in Western countries [1–5]. Therefore, more than half of cases of PUD are diagnosed predominantly when complicated. Conversely, in adults PUD is one of the commonest gastrointestinal disorders. Similarly, the vast majority of reported PPU cases involve adults as well. The annual incidence of perforated gastric or duodenal ulcer in adults ranges from 3.8 to 14.0 per 100,000 inhabitants [6]. However, paediatric PPU is a rare entity, particularly in females, with a questionable and varying incidence in different geographical regions. Here, we report our experience with PPU in children treated successfully.

Methods

A retrospective, single-centre review of all patients up to 18 years diagnosed with perforated peptic ulcer was conducted. Both gastric and duodenal ulcer patients admitted to Vilnius University Hospital Santariskiu Klinikos Children's Surgery Centre between October 1994 and April 2012 were included. Identification of patients was performed using ICD-10 codes (K25.1, K25.2, K25.5, K25.6, K26.1, K26.2, K26.5 and K26.6) from the hospitals' administrative electronic database or manually from hospital records and surgical notes. Patients with gastric or duodenal ruptures (due to blunt or penetrating trauma) were excluded. The data were analysed for the following variables: age, sex, anamnesis, clinical features, physical and instrumental examination

results, duration of perforation, operative findings and methods, medication therapy management and outcomes. Statistical analysis was performed using MS Excel. Ethical approval to conduct the study was obtained from relevant authority before its commencement.

Results

From 1994 to 2012, fifteen paediatric patients were treated for perforated peptic ulcer. There were 14 males (93.3%) and 1 female, aged 14 to 18 years (16.3 ± 1.3) included in the study. Twelve patients (80%) were diagnosed with gastric and 3 (20%) with duodenal PPU.

Eleven patients (73.3%) had dyspepsia before PPU, 4 of them had a history of peptic ulcer disease. Four (26.6%) had no past history of peptic ulcer disease or dyspepsia (Table 1). All patients denied cigarette, alcohol and illicit drug usage, as well as NSAIDs, steroid or other medication use. Seven (46.6%) patients arrived to hospital within 6 hours, three (20%) between 6–12 hours, two (13.3%) between 12–24, and three (20%) 24 hours after the onset of symptoms, 2 of whom had recurrent symptoms for 1 week.

The analysis of the clinical features of patients with PPU is shown in Fig. A. All patients presented to the

Table 1. Past medical history of dyspepsia, chronic abdominal pain and PUD

	Symptoms/status before perforation	No. of patients (%)
Positive (73.3%)	Nagging upper abdominal pain* for the period of: 1 week	5 (33.3%)
	3 months	2
	12 months	1
	PUD diagnosed before*	4 (26.6%)
	An episode of severe epigastric pain 1 week ago*	1 (6.6%)
	Recurrent spasmodic abdominal pain for two years* * plus dyspepsia	1 (6.6%)
Negative (26.6%)	None	4 (26.6%)

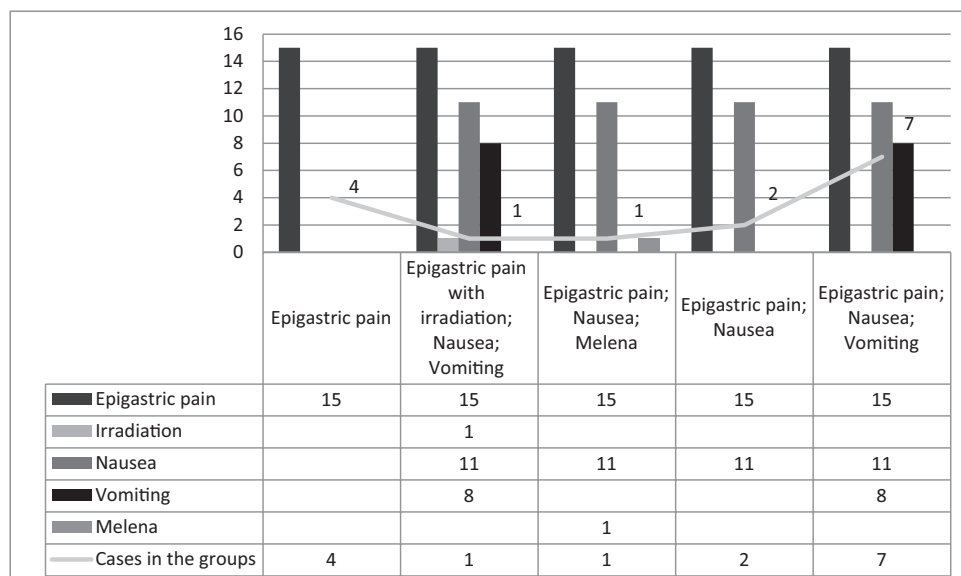


Figure A. Clinical features and combinations of symptoms

emergency department with a sudden onset of severe stabbing pain in the epigastrium, 8 (53.3%) with nausea and vomiting. Only one patient (6.6%) complained of melena. One patient (6.6%) suffered from epigastric pain radiating to the left shoulder as well. The commonest combination of symptoms was epigastric pain, nausea, and vomiting (46.6%).

Figure B presents the results of physical and instrumental examination of 15 patients with PPU on the admission day. Abdominal examination revealed positive peritoneal signs such as abdominal tenderness, guarding and the Blumberg sign in 13 patients (86.6%). Weak or absent peristalsis was encountered in 12 out

of 15 patients. Subdiaphragmatic free air was detected by radiography in 12 patients (80%) as well. Seven patients were sonoscopically scanned with findings of fluid and free air in the peritoneal cavity of 3 and 1 patients, respectively. On the next day signs of peritoneal irritation and specific radiographic changes occurred in two more inpatients. In 7 out of 15 patients, the combination of positive peritoneal signs, weak peristalsis or silent abdomen, pneumoperitoneum, neutrophilic leukocytosis and normal or subfebrile temperature were most frequent.

The mean duration of perforation was 34.47 ± 57.41 hours (2–178). The mean length of time between admission and surgery was 5.6 ± 5.78 hours (1–20 hours). Thirteen patients (86.6%) underwent

laparotomy, two (13.3%) – laparoscopic repair, one of them had a laparoscopic procedure converted to open repair because of technical difficulties and subsequent inability to obtain the appropriate laparoscopic closure. Upper midline laparotomy incisions were made. There was bile secretion in the peritoneal cavity in 6 out of 15 cases. PPU was complicated with peritonitis in all patients: 4 (26.6%) – local, 8 (53.4%) – diffuse, 3 – (20%) total. The anterior wall of the prepyloric gastric region was the commonest perforation site (80%). The perforated duodenal bulb was found in 3 cases (20%). The mean perforation diameter was 5.13 ± 2.16 mm (3–10 mm). Twelve ulcers (80%) were double-row

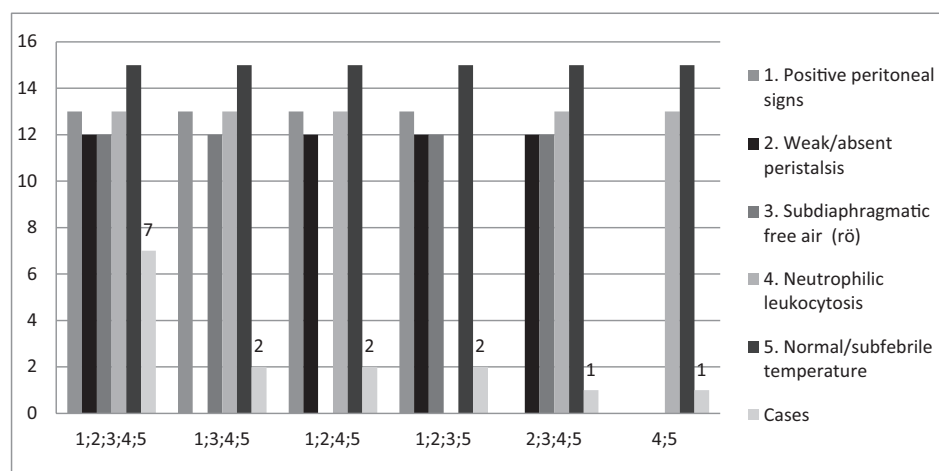


Figure B. Results of physical and instrumental examination on admission day

Antibacterial therapy of cefuroxime or gentamicin plus metronidazole was most often used (80%); one (6.6%) patient received cefuroxime alone, one – cefotaxime, gentamicin, and metronidazole, one – moxifloxacin, amoxicillin, clavulanic acid combination. Only 4 out of 15 patients were tested for *H. pylori* infection, 2 of them were positive. Four patients (26.7%) had ra-

Table 2. Operative findings of children with PPU

	Features	No. of patients (%)
Surgical procedure	Laparotomy	13 (86.6%) +1
	Laparoscopic repair	2 (13.3%) –1
	<ul style="list-style-type: none"> • Single-row suture • Double-row suture: covered with omental patch 	3 (20%) 12 (80%) 6 (50%)
Site of perforation	Anterior wall of prepyloric gastric region	12 (80%)
	Duodenal bulb	3 (20%)
Size of PPU	3–10 mm	15 (100%)
PPU complications	Peritonitis	15 (100%)
	<ul style="list-style-type: none"> • Local 	4 (26.6%)
	<ul style="list-style-type: none"> • Diffuse 	8 (53.3%)
	<ul style="list-style-type: none"> • Total 	3 (20%)

nitidine therapy (until 1990), in 11 cases (73.4%) – intravenous omeprazole and famotidine instituted as soon as PPU had been suspected. Two *H. pylori*-positive and 6 out of 11 untested patients had a course of *H. pylori* eradication therapy given twice daily with omeprazole +/- ranitidine for one month plus amoxicillin and metronidazole or amoxicillin and clarithromycin for the period of 2 weeks. The average hospital stay was 10.6 ± 6.3 days (4–32 days). Fourteen patients (93.3%) had an uneventful postoperative period, and one developed nephrotic range proteinuria.

Discussion

The peptic ulcer disease is an uncommon condition in paediatric surgical practice. However, complications of PUD, particularly the perforation of the gastric or duodenal ulcer with peritonitis, are even rarer but life-threatening surgical emergency in this age group.

As the literature declares, primary ulcers usually occur in children older than 10 years of age, usually are chronic, caused by *Helicobacter pylori* (*H. pylori*) infection and situated in the duodenum [7]. The age and gender distribution in our study shows the predominance of PPU in adolescent (100%) boys (93.3%) as similarly observed in previous reports [1, 4, 8].

The vast majority of our patients (73.3%) had a history of dyspepsia, and 36.4% of them had a positive anamnesis of PUD. Still 26.6% of patients had no digestive system symptoms before, suggesting that

perforation was the first manifestation of PUD with a predictably higher risk for complications. As reported in a series by Hua et al., the female sex, coexisting clinical events before PPU and no evidence of chronic ulcer were significantly associated with complications in patients with PPU [8].

Of our patients, 80% were diagnosed with gastric perforated peptic ulcer, giving further support to the prevailing opinion that duodenal peptic ulcers are more prevalent, although gastric ulcers perforate more frequently among children.

A sudden onset of a severe epigastric pain accompanied by nausea and vomiting appeared to be the typical clinical presentation in the patients with PPU (46.6%). One of our patients (6.6%) with a suspected upper gastrointestinal (GI) hemorrhage complained of melena and 1 suffered from epigastric pain radiating to the left shoulder. Similarly, Schwartz et al. reported a case of a 14.5-year-old adolescent girl with PPU, who developed abdominal and shoulder pain [1]. Thus, we suggest that melena and epigastric pain radiating to the shoulder should be suspected as a presentation of the upper GI bleeding with peptic ulcer perforation when managing children with peritonitis, particularly with a history of PUD or dyspepsia.

We strongly believe that the positive peritoneal signs suggesting an acute abdomen, subdiaphragmatic free air in the plain X-ray of the chest and abdomen, diminished bowel activity are crucial factors of physical and instrumental examination in children for the diagnosis

of PPU. We state that no other investigation is required in the emergency settings. However, when there are no radiographic changes, ultrasound or computed tomography would be appropriate for detecting indirect signs of stomach or duodenum perforation [8]. In still unclear situations, fibrogastroduodenoscopy is the preferred technique for the direct visualization of gastroduodenal pathology [7].

Late-presenting patients commonly are toxic and dehydrated. Therefore, a prompt recognition, medical fluid resuscitation, and the correction of electrolytes and acid-base disorder, surgical management are essential for the survival. Previous studies have shown that a higher rate of postoperative complications and a poorer outcome are related to a delay in the treatment [9, 10]. The latter depends on the time between the onset of symptoms and hospital arrival, on the time between admission and surgery, all in all on the duration of perforation. Thus, the primary operative repair should be performed whenever feasible.

Simple closure has been cited as a sufficient method of PPU treatment and a definitive ulcer surgery with a highly selective vagotomy, truncal vagotomy with drainage, and partial gastrectomy is no longer justified in paediatric patients [11]. Moreover, vagotomy in children can cause more gastrointestinal dysfunction than in adults [12]. According to multiple reports, an omental patch covering the affected area is the most preferable to use [4, 7, 8]. However, double and single-row sutures at our hospital are considered to be an adequate and safe closure for paediatric PPU in a large majority of cases. Still, 40% of our patients had perforated ulcers double-row sutured and covered with an omental patch for more safety. This inequality in surgical methods may be caused by different clinical practice of our surgeons, especially when working on call. Furthermore, the simple suture with an omental patch technique could be defined as an excessive caution when managing children with PPU. All in all, the use of both double-row suture or simple suture covered with an omental patch had not resulted in any intraabdominal abscesses, wound infections or leakages in 15 paediatric patients treated for PPU in our hospital.

Of our patients, 86.6% had laparotomy and subsequent ulcerorhaphy performed. However, the results of some clinical trials suggest that laparoscopic surgery could

be a safe and effective strategy for the routine clinical practice of paediatric patients with PPU [13–15]. Minimal access surgery was associated with a significantly lower wound infection, reduced postoperative pain and analgesic consumption, a lower mortality rate and a shorter hospital stay [13–16, 18–20]. Laparoscopy is also preferred when managing patients with acute abdomen and no radiographic changes [21]. However, this technique has a longer operating time and is not recommended for hypotensive patients, patients with a coexisting medical disease or previous upper abdominal surgery, in critical condition and in the presence of some technical difficulties or large ulcers [13–16, 18–20]. Thus, our Children's Surgery Centre, reaching for more advance in minimally invasive surgery of PPU, also suggests laparoscopy for low-risk patients. We invite to consider laparotomy as a certified method, particularly when the laparoscopic approach is difficult due to ulcer size and location, the degree of local inflammation, and the surgeon's expertise.

The approach of mandatory *H. pylori* eradication therapy is still supported by many scientists and MDs when managing *H. pylori*-positive children with PPU. In that case, the surgical procedure should be followed by the treatment of the underlying cause with the proton-pump inhibitor +/- histamine H₂-receptor antagonist for one month plus two antibiotics (amoxicillin plus metronidazole or amoxicillin plus clarithromycin) for the period of 2 weeks [22]. Not all our patients were tested for *H. pylori* infection due to previous belief of an implicit association between peptic ulcers, particularly duodenal, and the mentioned infection. Therefore, 6 out of 11 untested patients had also received "prophylactic" antibiotics for *H. pylori* eradication. Our current practice is fairly different: as *H. pylori*-negative PPU become more frequent, all patients with gastroduodenal perforation should be examined for *H. pylori* infection, and triple eradication therapy is instituted for confirmed infections only. According to Koletzko et al., the initial diagnosis of *H. pylori* infection is based on either a positive histopathology plus a positive rapid urease test or a positive culture, while the ¹³C-urea breath test (UBT) is appropriate to confirm the eradication of *H. pylori* after the treatment [22]. Moreover, it is offered to test serum gastrin levels to eliminate the Zollinger–Ellison syndrome for patients with primary ulcer and PPU [7].

Conclusions

Gastroduodenal ulcers usually perforate in adolescent (100%) boys (93.3%). The vast majority of patients have a history of dyspepsia or PUD (73.3%) before the perforation, however, some manifest with PPU without any previous symptoms. The anterior wall of the prepyloric gastric region is one of the commonest sites of PPU (80%). A sudden onset of severe epigastric pain accompanied by nausea and vomiting is the typical presentation of PPU (46.6%), although we also should think of melena and shoulder pain as the presentation of perforation and GI bleeding when managing children with peritonitis, particularly with a history of PUD or dyspepsia. Positive peritoneal signs, subdiaphragmatic free air in the plain X-ray of the chest and abdomen, and diminished bowel activity are crucial factors for the diagnosis of PPU, and no other

investigation is required in the emergency settings. Simple closure with or without an omental patch and subsequent eradication of *H. pylori* are integral in the management of perforated peptic ulcer. We suggest laparoscopy as a safe emergency procedure for low-risk patients with PPU, laparotomy to be considered as a certified method when the laparoscopic approach is difficult or inappropriate to perform. Double and single-row sutures are considered to be an adequate and sufficient closure for paediatric patients with PPU at our hospital. All patients with peptic ulcer perforation should be examined for *H. pylori* infection and triple eradication therapy instituted for confirmed infections only. Because of a small number of patients, the further study may also be needed to advance the technique of a prompt and effective diagnosis and management of PPU in children.

REFERENCES

- Schwartz S, Edden Y, Orkin B, et al. Perforated peptic ulcer in an adolescent girl. *Pediatr Emerg Care* 2012; 28(7): 709–711.
- Lee NM, Yun SW, Chae SA, et al. Perforated duodenal ulcer presenting with massive hematochezia in a 30-month-old child. *World J Gastroenterol* 2009; 15(38): 4853–4855.
- Quinn S, Rowland M, Drumm B. Peptic ulcer disease in children. *Curr Paediatr* 2003; 13: 107–113.
- Wong BPY, Chao NSY, Leung MWY, et al. Complications of peptic ulcer disease in children and adolescents: minimally invasive treatments offer feasible surgical options. *J Pediatr Surg* 2006; 41(12): 2073–2075.
- Tam YH, Lee KH, To KF, et al. Helicobacter pylori-positive versus Helicobacter pylori-negative idiopathic peptic ulcers in children with their long-term outcomes. *J Pediatr Gastroenterol Nutr*. 2009; 48: 299–305.
- Stewart DJ, Ackroyd R. Peptic ulcers and their complications. *Surg (Oxford)* 2008; 26(11): 452–457.
- Sullivan BP. Peptic ulcer disease in children. *Paediatrics and Child Health* 2010; 20(10): 462–464.
- Hua M-C, Kong M-S, Lai M-W, et al. Perforated peptic ulcer in children: A 20-year experience. *J Pediatr Gastroenterol Nutr* 2007; 45: 71–74.
- Svanes C, Lie RT, Lie SA, et al. Survival after peptic ulcer perforation: a time trend analysis. *J Clin Epidemiol* 1996; 49: 1363–1371.
- Cohen MM. Treatment and mortality of perforated peptic ulcer: a survey of 852 cases. *Can Med Assoc J* 1971; 105: 263–269.
- Zittel TT, Jehle EC, Becker HD. Surgical management of peptic ulcer disease today – indication, technique and outcome. *Langenbecks Arch Surg* 2000; 385: 84–96.
- Johnstone JM, Rinstoul RF. Perforated duodenal ulcer in childhood. *Br J Surg* 1972; 59: 288–289.
- Lee FY, Leung KL, Lai PB, et al. Selection of patients for laparoscopic repair of perforated peptic ulcer. *Br J Surg* 2001; 88: 133–136.
- Michelet I, Agresta F. Perforated peptic ulcer: laparoscopic approach. *Eur J Surg* 2000; 166: 405–408.
- Kujath P, Schwandner O, Bruch HP. Morbidity and mortality of perforated peptic gastroduodenal ulcer following emergency surgery. *Langenbecks Arch Surg* 2002; 387: 298–302.
- Zaji N. Laparoscopic repair of perforated peptic ulcers versus conventional open surgery. *Laparoscopyhospital Web site*. http://www.laparoscopyhospital.com/laparoscopic_repair_of_perforated_peptic_ulcers.html. Accessed August 13, 2014.
- Aldrink JH, Sowande OA. Peptic Ulcer Disease. *Paediatric Surgery: A Comprehensive Textbook for Africa*, Seattle: Global-HELP Organization, 2010.
- Lunevicius R, Morkevicius M. Systematic review comparing laparoscopic and open repair for perforated peptic ulcer. *Br J Surg* 2005; 92: 1195–1207.

19. Druart ML, Van Hee R, Etienne J, et al. Laparoscopic repair of perforated duodenal ulcer. A prospective multicenter clinical trial. *Surg Endosc* 1997; 11: 1017–1020.
20. Lunevicius R, Morkevicius M. Risk factors influencing the early outcome results after laparoscopic repair of perforated duodenal ulcer and their predictive value. *Langenbeck Arch Surg* 2005; 390(5): 413–420.
21. Siu WT, Chau CH, Law BK, et al. Routine use of laparoscopic repair for perforated peptic ulcer. *Br J Surg* 2004; 91: 481–484.
22. Koletzko S, Jones NL, Goodman KJ, et al. Evidence-based guidelines from ESPGHAN and NASPGHAN for *Helicobacter pylori* infection in children. Clinical Guidelines 2011. Guideline Web site: <http://www.guideline.gov/content.aspx?id=37875>. Accessed July 27.
23. Ng EK, Lam YH, Sung JJ, et al. Eradication of *Helicobacter pylori* prevents recurrence of ulcer after simple closure of duodenal ulcer perforation: randomized controlled trial. *Ann Surg* 2000; 231(2): 153–158.