

ISSN 1392-0995, ISSN 1648-9942 (online)

DOI: <https://doi.org/10.15388/LietChirur.2017.1.10491>

<http://www.chirurgija.lt>

LIETUVOS CHIRURGIJA

*Lithuanian Surgery*

2017, 16 (2), p. 125–128

# Unusual metastasis from rectal cancer: case report

## Neįprastas tiesiosios žarnos vėžio metastazavimas: atvejo pristatymas

Justas Kuliavas<sup>1</sup>, Audrius Dulskas<sup>1</sup>, Julius Drachneris<sup>2</sup>, Edita Mišeikytė Kaubrienė<sup>3,4</sup>,  
Narimantas E. Samalavičius<sup>1,3</sup>

<sup>1</sup> National Cancer Institute, 1 Santariškių Str., LT-08660 Vilnius, Lithuania

<sup>2</sup> State Pathology Center, 5 Baublio Str., LT-08406 Vilnius, Lithuania

<sup>3</sup> Centre of Oncosurgery, National Cancer Institute; Clinic of Internal, Family Medicine and Oncology, Faculty of Medicine, 2 Santariškių Str., LT-08661 Vilnius, Lithuania

<sup>4</sup> Department of Radiology, National Cancer Institute, 1 Santariškių Str., LT-08660 Vilnius, Lithuania  
E-mail: justas.kuliavas@gmail.com

<sup>1</sup> Nacionalinis vėžio institutas, Santariškių g. 1, LT-08660 Vilnius, Lietuva

<sup>2</sup> Valstybinis patologijos centras, Baublio g. 5, LT-08406 Vilnius, Lietuva

<sup>3</sup> Nacionalinio vėžio instituto Onkochirurgijos centras, Vilniaus universiteto Medicinos fakulteto Vidaus ligų šeimos medicinos ir onkologijos klinika, Santariškių g. 2, LT-08661 Vilnius, Lietuva

<sup>4</sup> Nacionalinio vėžio instituto Radiologijos skyrius, Santariškių g. 1, LT-08406 Vilnius, Lietuva  
El. paštas: justas.kuliavas@gmail.com

---

Metastasis of rectal cancer to the penis is a very rare condition with less than 40 cases found in the literature. The prognosis is poor and life expectancy is short. The mechanism of rectal cancer metastasis spread to penis is unknown. The most popular theory is retrograde venous spread. There are several treatment options, but no single treatment option has emerged with superior results. The authors report a case of a 41 old man who was diagnosed with rectal cancer, treated with neoadjuvant radiotherapy, underwent rectal resection, had adjuvant chemotherapy, and despite that, 2 years after had penal metastasis. After diagnosis, he survived 2 months.

**Key words:** penile metastasis, rectal cancer, prognosis, treatment, penis

---

Labai retai tiesiosios žarnos vėžio metastazės plinta į varpą. Literatūros duomenimis, tokių atvejų yra aprašyta mažiau kaip 40. Prognozė yra bloga ir išgyvenamumas trumpas. Tiesiosios žarnos vėžio metastazių plitimo į varpą mechanizmas nežinomas. Populiariausia teorija yra apie retrogradinį veninį plitimą. Aprašoma keletas gydymo metodų, tačiau nė vienas nėra pranašesnis. Autoriai pristato 41 metų amžiaus vyro klinikinį atvejį. Vyruvi buvo diagnozuotas tiesiosios žarnos vėžys, prieš operaciją taikyta radioterapija, paskui operacinis gydymas ir pooperacinė chemoterapija. Nepaisant to, po dvejų metų išsivystė metastazės varpoje. Po metastazių diagnozės ligonis išgyveno du mėnesius.

**Reikšminiai žodžiai:** metastazės varpoje, tiesiosios žarnos vėžys, prognozė, gydymas, varpa

---

### Abbreviations & Acronyms

MTS = metastasis  
 LAR = low anterior resection  
 APR = abdominoperineal resection  
 CT = computer tomography  
 PET CT = positron emission computer tomography  
 MRI – magnetic nuclear resonance imaging

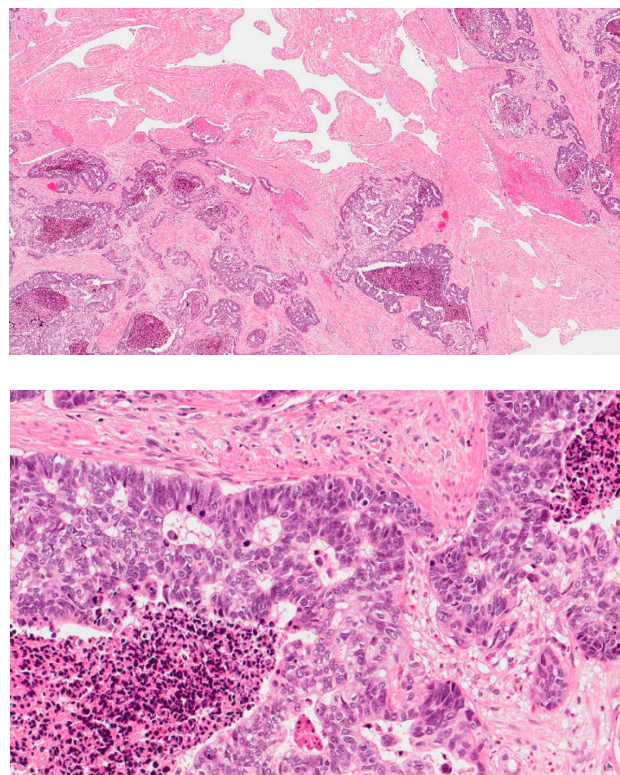
### Introduction

Rectal cancer is not a rare disease. It mainly metastasises to regional lymph nodes, liver, lung, and bones. Metastatic involvement of the penis in rectal carcinoma is a very rare condition. The first case was reported in 1870 by Eberth [1]. Other more frequent primary sites of origin are bladder (33%), prostate (30%), colon (17%), and kidney (7%) [2]. We have performed a literature search and found only 38 cases of rectal cancer spreading to the penis. Here we report a case of 41 year old man who underwent rectal resection, was treated with adjuvant chemoradiotherapy, and later developed metastases to the penis.

### Case report

A 41 year old man diagnosed with rectal cancer without distant metastases, underwent preoperative radiotherapy in October, 2007 (with a total dose of 25 Gy in 5 fractions). In 5 days the patient underwent rectal resection. Final histopathology report was pT2N1M0 stage III adenocarcinoma. Surgical margins were negative and 2 of 14 lymph nodes were positive. The patient recovery was uneventful. The patient then was given adjuvant chemotherapy with 5-Fluorouracil (5-FU) 425 mg/m<sup>2</sup> i/v. 1–5 d, Calciumfolinat – 20 mg/m<sup>2</sup> i/v. 1–5 d, repeated every for 4 week, for 6 courses. No clinical or radiological evidence of recurrence was observed for 17 months after rectal resection until he started complaining of dysuria. Pelvic CT was performed. There was a suspicion of direct cancer spread to the neck of the bladder. Transurethral resection of bladder was performed. Histopathology revealed intestinal spread of adenocarcinoma. After two months, the patient complained of pain, and swelling of the penis and scrotum. On examination, a hard 0.5 cm nodule on the penis and an induration involving the right corpora cavernosa were noted. A biopsy of the nodule revealed

metastases of the adenocarcinoma. The patient underwent a palliative penectomy and bilateral orchiectomy with suprapubic cystostomy. Histopathology study results revealed intestinal adenocarcinoma metastases in the penis (see Figure). The patient refused chemotherapy and died in two months.



**Figure.** Glandular and cribriform structures with „dirty necrosis“, typical of intestinal type adenocarcinoma, infiltrating *corpus cavernosum*

### Discussion

Metastatic involvement of the penis is rare, despite its rich vascular supply and its proximity to the rectum, bladder and prostate, which are common sites of malignancy. In our review, we found that penile metastases from rectal cancer is usually present on an average of 37 months after treatment of the primary tumour. Nevertheless, by removing two cases where metastases appeared in the 9th and 26th year [2, 3] after the primary treatment, the average onset of penile metastases was 25 months. Two-thirds of the patients had disse-

minated metastases at presentation [4]. Occasionally, penile metastases can be a synchronous finding [5, 6], or present as a leading symptom of the disease [6]. The most common symptoms noted, were palpable nodule, lesion/ulceration, priapism and difficulty voiding. Two patients had no symptoms [7, 8]. In our case, the patient complained of difficult voiding, pain and swelling in the scrotum and penis. Patient underwent rectal cancer surgery two years ago.

The mechanism of metastatic spread to the penis is not well established. Despite sufficient blood supply and close proximity to pelvic malignancies, penile metastasis is very rare, and the route by which it is spread, is still a matter of controversy. Already in 1956, Paquin and Roland [9] proposed the following modes of dispersal: direct extension, retrograde venous transportation, retrograde lymphatic transportation, secondary embolism from lung metastases, tertiary embolism from liver metastases, direct extension into arterial pathways, and instrumentation. Most investigators suggest that retrograde venous transportation is the main mechanism involved in the development of secondary penile tumours [10]. In our case, direct dispersal is likely to occur from the rectal tumour along the perineal planes, and then reach the bladder; and during the transurethral resection of the bladder, it was disseminated to the penis.

Diagnosis is usually made by a biopsy, which helps to differentiate between metastasis and primary tumours. The favoured non-invasive imaging modality to delineate the extent of involvement of the penis is MRI [5, 7]. On T1-weighted images, lesions have low signal intensity, isointense with the surrounding *corpus cavernosum*. On T2-weighted imaging, they appear inhomogeneous with low to intermediate signal intensity, seen clearly against the high background intensity of the cavernosal

bodies. Other radiological diagnostic modalities such as CT and PET are useful non-invasive methods for the evaluation of lesions [7, 8]. Invasive methods such as cavernosography may be used. It is useful to delineate the extent of involvement of the corporal bodies. Metastatic lesions usually are seen as filling defects or structural deformities of the corporal bodies or glans. In the presence of malignant priapism, obstruction of penile venous flow can also be demonstrated. But it is disliked because of invasiveness.

Regardless of the treatment option chosen, prognosis of penile metastases remains poor, with an average survival, in our review, of only 7 months. This might reflect the fact that penile metastases usually indicate a widely disseminated disease. In our case, the patient survived only 2 months after the onset of the urinary problems and the surgical treatment. Treatment options include surgical excision, radiotherapy, chemotherapy and symptomatic management. Although only small treatment groups are available for comparison. No single treatment option with superior results has been noted. Total penectomy remains the only treatment to have shown a longer-term survival in patients with localized disease [7]. Surgery might also have a role in palliation where there is intractable penile pain [4].

In conclusion, secondary malignancy of the penis is an uncommon clinical entity with less than 40 cases reported. The common mode of spreading to the penis is by the retrograde venous route. However, in the case presented, direct spreading may have been what occurred. The overall outcome is very poor and most patients will need only palliative or supportive care.

**Conflict of interest:** None declared.

## REFERENCES

1. Eberth CJ. Krebsmetastasen den corpus cavernosum penis. *Virchow's Arch. T. Path. Anat.* 1870; 74: 145.
2. Ketata S, Boulaire JL, Soulimane B, Bargain A. Metachronous metastasis to the penis from a rectal adenocarcinoma. *Clin Colorectal Cancer* 2007; 6: 657–9.
3. Tagart REB. Secondary deposit of rectal carcinoma in the penis. *Proceedings of the Royal Society of Medicine* 1967; 60: 501.
4. Haddad FS, Manne RK. Involvement of the penis by rectocolic adenocarcinoma. Report of a case and review of the literature. *Dis. Colon Rectum* 1987; 30: 123–29.
5. Chung TS, Chang HJ, Kim DY et al. Synchronous penile metastasis from a rectal carcinoma. *Int. J. Colorectal Dis.* 2008; 23: 333–4.
6. Cholin L, Perz S, Mahmood F, Zafar S. Palpable penile metastases: a bizarre presentation of rectal adenocarcinoma. *Case Reports in Urology* 2015; 2015: 1–3.
7. Kimura Y, Shida D, Nasu K, Matsunaga H, Warabi M, Inoue S. Metachronous penile metastasis from rectal cancer after total pelvic exenteration. *World J Gastroenterol.* 2012; 18: 5476–8.
8. Alzayed MF, Artho G, Nahal A, Hickeson M. Penile metastasis from rectal cancer by PET/CT. *Clin Nucl Med.* 2015; 40: 245–50.
9. Paquin AJ Jr, Roland SI. Secondary carcinoma of the penis. A review of the literature and a report of nine new cases. *Cancer* 1956; 9: 626–32.
10. Papaefthymiou V, Hall A, Ladoyanni E. Metachronous metastasis to glans penis from colorectal cancer. *Austin J Dermatolog.* 2014; 1: 1002.