

Oligometastatic breast cancer: a case report and literature review

Oligometastazinis krūties vėžys: klinikinio atvejo aprašymas ir literatūros apžvalga

Valerijus Ostapenko¹, Saulius Cicėnas¹, Andrejus Ostapenko¹, Rūta Briedienė¹,
Edvinas Ostapenko²

¹ *National Cancer Institute, Santariskiu Str. 1, LT-08660 Vilnius, Lithuania*

² *Faculty of Medicine, Vilnius University, M. K. Čiurlionio Str. 21, LT-03101 Vilnius, Lithuania*
E-mail: v.ostapenko@takas.lt

¹ *Nacionalinis vėžio institutas, Santariškių g. 1, LT-08660 Vilnius, Lietuva*

² *Vilniaus universiteto Medicinos fakultetas, M. K. Čiurlionio g. 21, LT-03101 Vilnius, Lietuva*
El. paštas: v.ostapenko@takas.lt

Introduction

Oligometastatic breast disease is a potentially curable state of distant cancer spread, but there is still no standard approach for treatment. The aim of this article is to present a clinical case of oligometastatic breast cancer and short data of the latest literature sources.

Case report

This case report presents 58 years old postmenopausal women diagnosed with oligometastatic breast carcinoma who underwent a successful simultaneous nipple-sparing mastectomy with sentinel node biopsy and right upper lobectomy in National Cancer Institute, Vilnius, Lithuania.

Conclusions

Multidisciplinary approach and modern imaging studies allows us to diagnose and successfully treat this rare pathological state. Scientific trials to delineate proper indications for oligometastatic breast disease are needed

Key words: oligometastatic disease, breast cancer, multidisciplinary team approach

Įvadas

Oligometastazinis krūties vėžys yra potencialiai pagydoma būklė, kuriai yra būdingas ribotas metastazinis išplitimas, tačiau iki šiol nėra gydymo standartų. Straipsnio tikslas – aprašyti retą oligometastazinio krūties vėžio atvejį, apžvelgti naujausius literatūros šaltinius ir įvertinti problemos aktualumą.

Klinikinis atvejis

Straipsnyje aprašomas 58 metų moters klinikinis atvejis – postmenopauzės laikotarpiu jai buvo diagnozuotas oligometastazinis krūties vėžys. Ligonė buvo gydyta chirurginiu būdu Nacionaliniame vėžio institute Vilniuje.

Išvados

Moderni radiologinė diagnostika ir daugiadalykės komandos darbas sudaro galimybes sėkmingai diagnozuoti ir gydyti šią retą onkologinę patologiją. Ateityje reikalingi moksliniai tyrimai oligometastazinio krūties vėžio gydymui standartizuoti.

Reikšminiai žodžiai: oligometastazinė liga, krūties vėžys, daugiadalykės komandos darbas

Introduction

Oligometastatic (OM) breast cancer (BC) – is a disease concept, which is defined by a state of limited systemic metastatic tumors. Limited means 1 to 5. These metastases are typically confined to one organ. In case we have more than 5 metastases it is a risk that tumor cells may acquire widespread metastatic potential. Multi-disciplinary approach and modern imaging studies allows us to diagnose and treat this rare pathological state. Oligometastatic breast cancer differs from multi-metastatic diseases in prognosis and survival rate. The identification of patients with oligometastatic disease is very important, because oligometastatic disease is a potentially curable state of distant cancer spread.

Case report

58 years old white postmenopausal woman complained the lump in her left breast. Woman found the lump during her monthly self-examination. Further patient examinations and treatment was performed in National Cancer Institute, Vilnius, Lithuania

Breast physical examination: in the upper quadrant of the left breast a palpable, freely movable, mass measures ~3 cm in diameter. No pain or tenderness; no nipple discharge; no skin changes, no nipple retraction. Left breast: no palpated masses. Axillary and regional lymph nodes – not enlarged.

The radiologic examination of this patient included: breast ultrasound, digital mammography, MRI, ultrasonography guided core breast biopsy, whole body CT scan, PET CT. The ultrasonography (Fig. 1) was performed, and mammography suggested a malignant mass (Bi-rads-V) (Fig. 2 and Fig. 3).

Additional radiologic examination (whole body MRI, PET CT scan) revealed a 2.5 cm tumor in an upper lobe of the right lung and metastatic lesions in a left iliac bone body (Fig. 4, Fig. 5, Fig. 6).

Preoperative breast and lung tumors biopsy was performed and invasive breast ductal carcinoma G2 HER2 positive 1+, ER negative 100% PR positive 80%, Ki-67 – 10% and lung adenocarcinoma G2 was confirmed.

Oligometastatic left breast carcinoma cT2N×M1 stage IV with metastasis to bones and peripheral upper

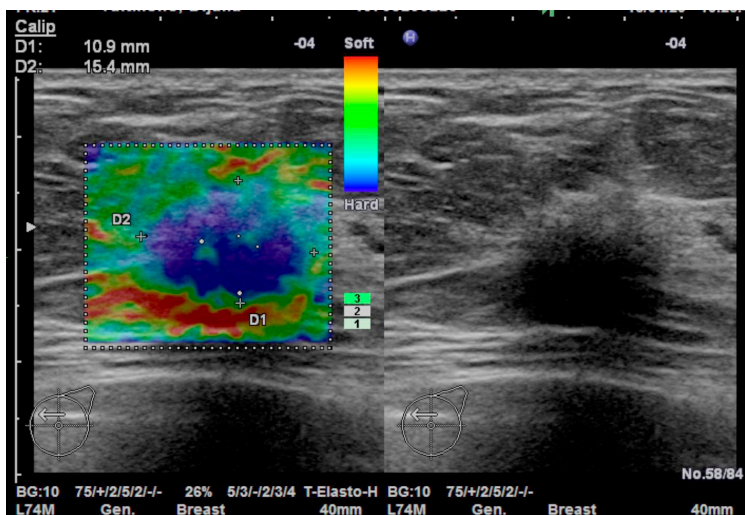


Figure 1. Ultrasonogram of breast pathological mass ~17mm. Elastography shows hard tissue (blue color)

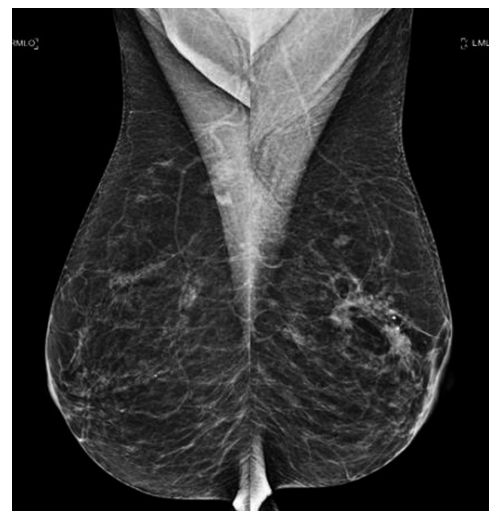

Figure 2. Right breast: mediolateral oblique view of normal breast

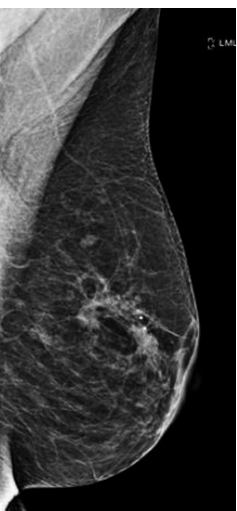


Figure 3. Left breast: 20 mm pathological mass with microcalcifies grouped in the left upper quadrant

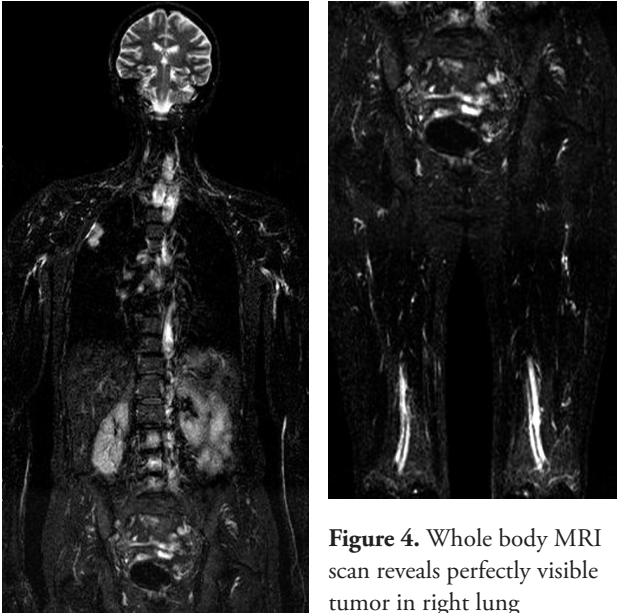


Figure 4. Whole body MRI scan reveals perfectly visible tumor in right lung

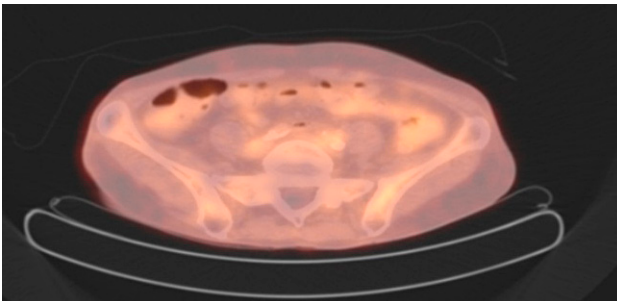


Figure 5. PET CT scan reveals slightly seen bone metastatic lesions/infiltration of left iliac body

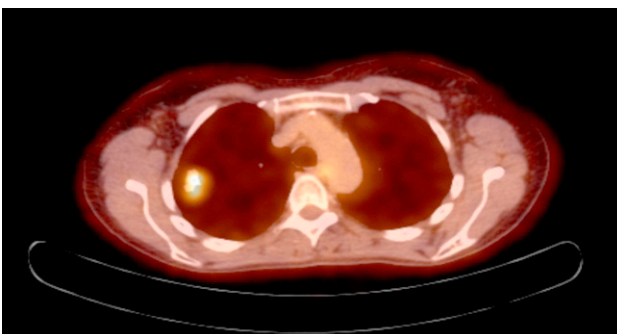


Figure 6. PET CT scan reveals perfectly visible tumor in right lung

lobe of the right lung carcinoma cT2N×M0 stage II were diagnosed and preoperative diagnosis was confirmed histologically by core biopsy. According to the extent of the oncologic disease and biologic type of breast cancer (luminal A), multidisciplinary team recommended simultaneous right lobectomy and left nipple sparing mastectomy with sentinel lymph node biopsy.

In April of 2016 combined simultaneous left nipple sparing mastectomy with sentinel node biopsy and upper right lobectomy were performed.

Postoperative diagnosis: oligometastatic left breast carcinoma pT2N0(sn)M1 stage IV. Metastasis to left iliac bone. Peripheral carcinoma in the right lung L1, pT1bN0M0 stage I.

Now patient is recovering in the rehabilitation clinic after surgery. Breast multidisciplinary team recommended whole body CT and adjuvant hormonotherapy for breast cancer treatment. After full body CT evaluation and rehabilitation – final breast and thoracic multidisciplinary team evaluation.

Discussion

The oligometastatic state implies that a few metastases (usually ≤ 5) exist before tumor cells acquire widespread metastatic potential [2]. Clinically, OM BC is characterized by solitary or few detectable lesions, usually limited to single organs, in which local therapy could affect survival. This population of ‘potentially curable’ stage IV disease is estimated to be 1–10% of newly diagnosed patients with metastatic BC [1]. Patients with OM disease can be divided into 3 cohorts [3, 4]: those who present with oligometastases; those with residual oligometastases after systemic therapy (ST); those with relapsed oligometastases after curative locoregional therapy. Most published series refer to an era before modern imaging (i.e. PET CT), and thus many patients were probably under-staged. Treatment purpose options must be evaluated, before starting treatment. State of oligorecurrence means that all the gross tumors could be treated with local therapy, meaning curative treatment. State of oligometastases means clinicians should judge whether a primary site can be controlled. If primary site is controlled, meaning oligorecurrence, they should pursue to cure the patients. In case primary site is un-

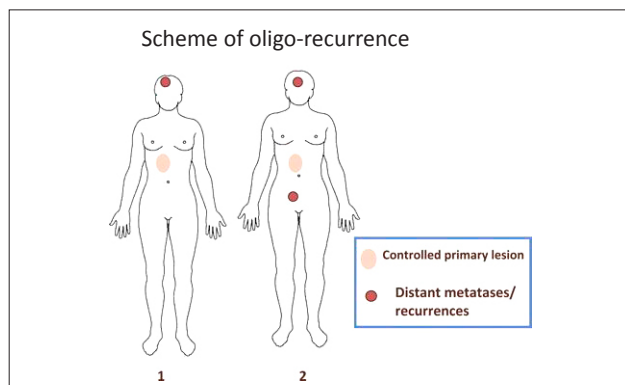


Figure 7. Scheme 1 shows one distant metastasis with a primary lesion. Scheme 2 shows two distant metastases with a primary lesion

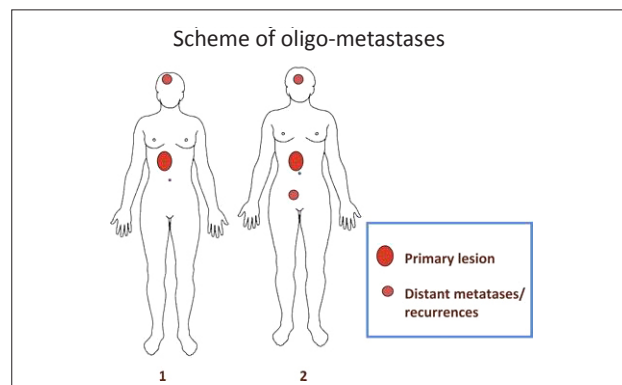


Figure 8. Scheme 1 shows one distant recurrence with a controlled primary lesion. Scheme 2 shows two distant recurrences with a controlled primary lesion

controlled or extra-target metastases lesions exist, they intend to prolong survival not to pursue cure [5, 8].

Multidisciplinary approach and modern imaging studies allows us to diagnose and treat this rare pathological state. Improved modern imaging and aggressive approaches are recommended in patients with only apparently limited disease [6].

Oligometastatic breast cancer differs from multi-metastatic diseases in prognosis and survival rate. The identification of patients with oligometastatic disease is very important, because oligometastatic disease is a potentially curable state of distant cancer spread. Sur-

vival rate of this narrow group of oligometastatic cancer patients are impressive: the local control at 3 years 89%, overall survival at 3 years 73% [7].

Conclusions

Oligometastatic breast cancer disease is a potentially curable state of distant cancer spread. There is still no standard approach for treatment. Every patient is unique and requires specific multidisciplinary approach. The identification of patients with oligometastatic disease is very important.

REFERENCES

1. Pagani O, Senkus E, Wood W et al. International guidelines for management of metastatic breast cancer: can metastatic breast cancer be cured? *J Natl Cancer Inst* 2010; 102: 456–463.
2. Weichselbaum RR, Hellman S: Oligometastases revisited. *Nat Rev Clin Oncol* 2011; 8: 378–382.
3. Niibe Y, Chang JY. Novel insights of oligometastases and oligo-recurrence and review of the literature. *Pulm Med* 2012; 12: 261–266.
4. Milano MT, Zhang H, Metcalfe SK et al. Oligometastatic breast cancer treated with curative-intent stereotactic body radiation therapy. *Breast Cancer Res Treat* 2009; 115: 601–608.
5. Di Lascio S, Pagania O. Oligometastatic breast cancer:

a shift from palliative to potentially curative treatment? *Breast Care* 2014; 9: 7–14.

6. Kirkpatrick J, Kelsey C, Palta M., Cabrera A, Salama JK, Patel P et al. Stereotactic body radiotherapy a critical review for nonradiation oncologists cancer 2014; 120: 942–954.

7. Navarria P, Ascolese AM, Tomatis S, Cozzi L, De Rose F, Mancosu P et al. Stereotactic body radiotherapy (sbrt) in lung oligometastatic patients: role of local treatments. *Radiation Oncology* 2014; 9: 91.

8. Niibe Y, Hayakawa K. Oligometastases and oligo-recurrence: the new era of cancer therapy. *Jpn J Clin Oncol* 2009; 40(2): 107–111.