

Two Novel Variants in Genes of Arrhythmogenic Right Ventricular Cardiomyopathy – a Case Report

Dovilė Gabartaitė*

Faculty of Medicine, Vilnius University, Vilnius, Lithuania
Centre of Cardiology and Angiology, Vilnius University
Hospital Santaros Klinikos, Vilnius, Lithuania

Dovilė Jančauskaitė

Faculty of Medicine, Vilnius University, Vilnius, Lithuania
Centre of Cardiology and Angiology, Vilnius University
Hospital Santaros Klinikos, Vilnius, Lithuania

Violeta Mikštienė

Department of Human and Medical Genetics, Faculty of
Medicine, Vilnius University, Vilnius, Lithuania

Eglė Preikšaitienė

Department of Human and Medical Genetics, Faculty of
Medicine, Vilnius University, Vilnius, Lithuania

Rimvydas Norvilas

Hematology, Oncology and Transfusion Medicine Center,
Vilnius University Hospital Santaros Klinikos, Vilnius, Lithuania

Nomeda Valevičienė

Centre of Radiology and Nuclear Medicine, Vilnius University
Hospital Santaros Klinikos, Vilnius, Lithuania

Germanas Marinskis

Faculty of Medicine, Vilnius University, Vilnius, Lithuania
Centre of Cardiology and Angiology, Vilnius University
Hospital Santaros Klinikos, Vilnius, Lithuania

Audrius Aidietis

Faculty of Medicine, Vilnius University, Vilnius, Lithuania
Centre of Cardiology and Angiology, Vilnius University
Hospital Santaros Klinikos, Vilnius, Lithuania

Jūratė Barysienė

Faculty of Medicine, Vilnius University, Vilnius, Lithuania
Centre of Cardiology and Angiology, Vilnius University
Hospital Santaros Klinikos, Vilnius, Lithuania

Summary. Background. Arrhythmogenic right ventricular cardiomyopathy (ARVC) is a heritable cardiomyopathy, characterized by fibrofatty replacement of myocytes in the right ventricular, left ventricular or both ventricles. It is caused by pathogenic variants of genes encoding desmosomal (*JUP*, *DSP*, *PKP2*, *DSG2*, *DSC2*) and non-desmosomal proteins, and is one of the most common causes of sudden cardiac death in young athletes. Therefore, early identification, correct prevention and treatment can prevent adverse outcomes.

Case report. Our case presents a 65-years-old man with recurrent ventricular tachycardia. The ischemic cause was the first to rule out. Echocardiography revealed right ventricular structural and functional abnormalities. After suspicion of ARVC, magnetic resonance imaging was performed showing reduced right ventricular ejection fraction with local aneurysms, structural changes in the right and left myocardium. Subsequently performed genetic testing identified a novel ARVC likely pathogenic variant in *DSC2* gene and variant of uncertain significance in *RYR2* gene.

Conclusions. Diagnostic evaluation of ARVC is challenging and requires multidisciplinary team collaboration. Further functional tests for elucidation of the clinical significance of the two novel variants of ARVC-associated genes could be suggested.

Keywords: arrhythmogenic right ventricular cardiomyopathy, ventricular arrhythmias, desmosomal mutations.

* Corresponding author: Dovilė Gabartaitė, Santariškių 2, LT-08661, Vilnius, Lithuania, E-mail: dovile.gabartaite@gmail.com

Du nauji aritmogeninės dešiniojo skilvelio kardiomiopatijos genų variantai – atvejo aprašymas

Santrauka. Apžvalga. Aritmogeninė dešiniojo skilvelio kardiomiopatija (ADSK) – paveldima širdies raumens liga, kuriai būdinga fibrozinė riebalinė dešiniojo skilvelio, kairiojo skilvelio ar abiejų skilvelių raumens degeneracija ir funkcijos sutrikimas. ADSK patogenezėje svarbi genetika, nes šią ligą sukelia genų, koduojančių desmosominius (*JUP*, *DSP*, *PKP2*, *DSG2*, *DSC2*) ir nedesmosominius baltymus, patogeniniai variantai, kurie yra viena iš dažniausių jaunų sportininkų staigios širdinės mirties (SŠM) priežasčių. Ankstyvas sergančių asmenų nustatymas, tinkamos prevencijos priemonės ir gydymas gali jiems išgelbėti gyvybę.

Atvejo aprašymas. Šiame darbe pristatomas 65 metų vyro, kuriam buvo besikartojanti skilvelinė tachikardija (SkT), klinikinis atvejis. Pirmiausia buvo atmesta galima išeminė SkT priežastis. Atlikus ultragarsinį širdies tyrimą buvo nustatyti struktūriniai ir funkciniai dešiniojo skilvelio (DS) pakitimai. Įtarta ADSK. Diagnozei patikslinti buvo atliktas širdies magnetinio rezonanso tyrimas (MRT), kuriuo nustatyta sumažėjusi DS išstūmio frakcija su lokaliomis aneurizmomis, struktūriniai pakitimai dešiniojo ir kairiojo skilvelių miokarde. Atlikus genetinį ištyrimą patvirtinti nustatyti desmokolino-2 (*DSC2*) geno patogeninis variantas ir rianodino receptoriaus 2 (*RYR2*) geno neaiškios klinikinės reikšmės variantas.

Išvados. ADSK diagnostika yra iššūkis gydytojui, reikėtų multidisciplininės komandos bendradarbiavimo. Reikia tolesnio ištyrimo, tai padėtų išsiaiškinti nustatytų genų variantų reikšmę.

Raktažodžiai: aritmogeninė dešiniojo skilvelio kardiomiopatija, skilvelinės aritmijos, desmosominių genų mutacijos.

Introduction

Arrhythmogenic right ventricular cardiomyopathy (ARVC; ORPHA:247) is a chronic, progressive, heritable cardiomyopathy, characterized by fibrofatty replacement and dysfunction of right ventricular, left ventricular or both ventricles muscle [1, 2]. It is one of the most common causes of sudden cardiac death (SCD) in young athletes, accounting for approximately 22 percent of cases [3]. Genetics plays an important role in pathogenesis of ARVC. It is caused by pathogenic variants of genes encoding desmosomal and non-desmosomal proteins [4]. The majority of the identified ARVC variants, classified as pathogenic or unknown in the disease genetic variant database, are in five most commonly mutated desmosomal protein genes: plakoglobin (*JUP*), desmoplakin (*DSP*), plakophilin-2 (*PKP2*), desmoglein (*DSG2*) and desmocollin-2 (*DSC2*) [5]. Desmosomal proteins dysfunction causes myocyte detachment from one another and cell death [6, 7]. It particularly happens when myocardium is placed under mechanical stress such as during physical activity [8, 9]. Also, there are number of non-desmosomal genes involved in ARVC-mimicking diseases: *TMEM43*, *CTNNA3*, *DES*, *LMNA*, *PLN*, *RYR2*, *TGFB3*, and *TTN* [1, 4, 10]. Early identification of patients, correct prevention and treatment can prevent SCD. The aim of this report is to present a 65-years-old man with an unusual clinical presentation of ARVC and discuss pathogenicity of the two novel identified variants in ARVC-associated genes.

Case report

65-years-old man was admitted by ambulance to the Vilnius University Hospital Santaros klinikos after having palpitations for the first time in his life. The patients' symptoms were accompanied by dizziness and weakness. Electrocardiogram (ECG) showed monomorphic ventricular tachycardia (VT) with left bundle-branch block morphology, heart rate was 202 beats per minute (BPM). Although Amiodarone infusion was administered to the patient, sinus rhythm was restored by synchronized electrical shock (150 J) due to the worsening of hemodynamic parameters. The man was monitored and observed in the hospital for the next 6 hours. No recurrent arrhythmia was observed and the next morning patient was discharged from the hospital.

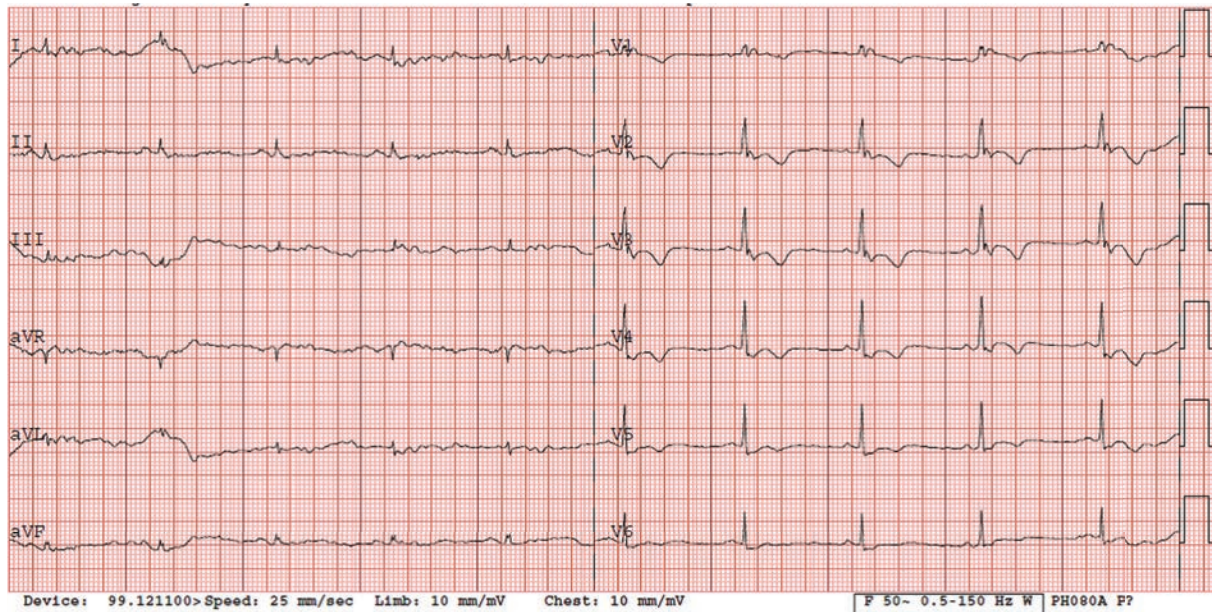


Fig 1. ECG during outpatient clinic cardiologist's consulting: inverted T waves in precordial leads (V1, V2, V3, V4, V5) and the presence of complete right bundle-branch block – minor criteria according to the 2010 revised Task Force criteria (2).
ECG – electrocardiogram.

Anamnesis revealed that the patient was consulted by a cardiologist in outpatient clinic three years ago due to episode of chest pain and dyspnea. ECG, lipidogram and exercise stress test were performed. ECG showed right bundle-branch block (RBBB) with T-wave inversion in V1-V5 leads (Fig. 1). According to the patient, ECG lesions have also been identified during previous preventive examinations. No pathological changes were observed in the lipidogram and exercise stress test.

After 2 weeks the patient was admitted to the hospital again because palpitation and chest discomfort. ECG (Fig. 2), performed in emergency room, revealed the episode of monomorphic VT with left bundle-branch block morphology (heart rate 202 BPM). Sinus rhythm was restored by electrical cardioversion (70 J). Due to unclear cause of recurrent ventricular tachycardia the patient was hospitalized for detailed examination. The first thought was of acute coronary syndrome, therefore coronary angiography was performed showing no stenosis in coronary arteries. For the differential diagnosis of heart failure or cardiomyopathies, echocardiography was carried out. Right ventricular (RV) structural and functional abnormalities were found: trabeculation of RV, mild enlargement, decreased RV systolic function and relaxation, nevertheless left ventricular (LV) ejection fraction was normal (> 53%), no signs of LV dilatation. It was the first visualization method, which let us to suspect ARVC. Subsequently magnetic resonance imaging (MRI) was performed and its findings justified the suspicion of diagnosis of ARVC: segmental contraction with the local aneurysms has been reported, RV ejection fraction was 21% (figure 3). Additionally, structural changes in the right (akinesia of RV inferior wall and dyskinesia of RV apex) and left myocardium (regional akinesia of LV posterior wall and regional hypokinesia of LV lateral wall with preserved LV EF) has been reported (figure 4, 5 - late gadolinium enhancement (LGE) images – structural changes – LGE in the right and left ventricles). The MR radiologist conclusion was one of the major ARVC criteria (according to Task Force 2010). These findings suggested ARVC diagnosis of biventricular involvement.

Patient had one major (MRI) criterion and two minor (repolarization disorders ECG and ventricular arrhythmia) criteria of ARVC: complete right bundle-branch block in ECG with T-wave

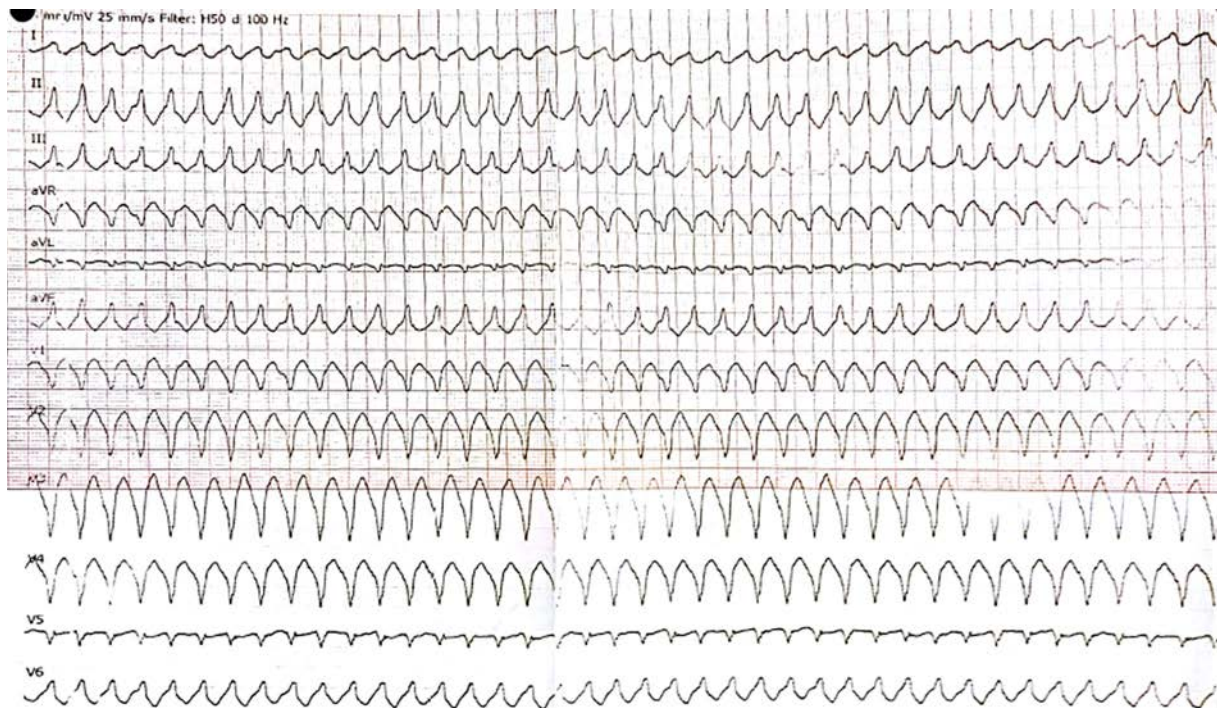


Fig 2. ECG performed in emergency room: VT with right ventricular (RV) outflow configuration, left bundle-branch block morphology with inferior axis (positive QRS in leads II, III, and aVF and negative in lead aVL) – minor criterion according 2010 revised Task Force criteria (2).
ECG – electrocardiogram, RV – right ventricular, VT – ventricular tachycardia.

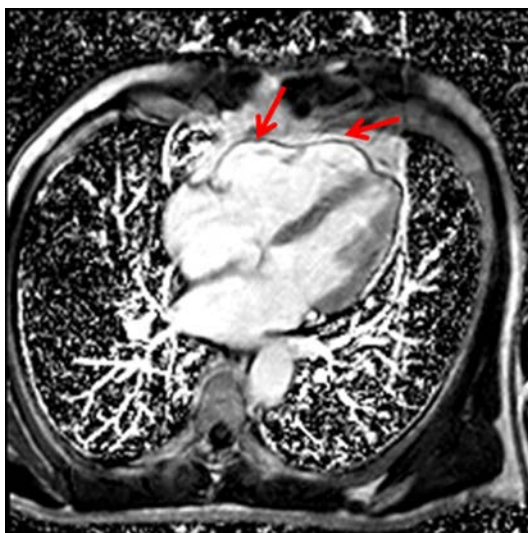


Fig. 3. 4 chamber LGE image. The RV local aneurysms has been reported in CMR.
CMR – cardiac magnetic resonance, LGE – late gadolinium enhancement, RV – right ventricle.

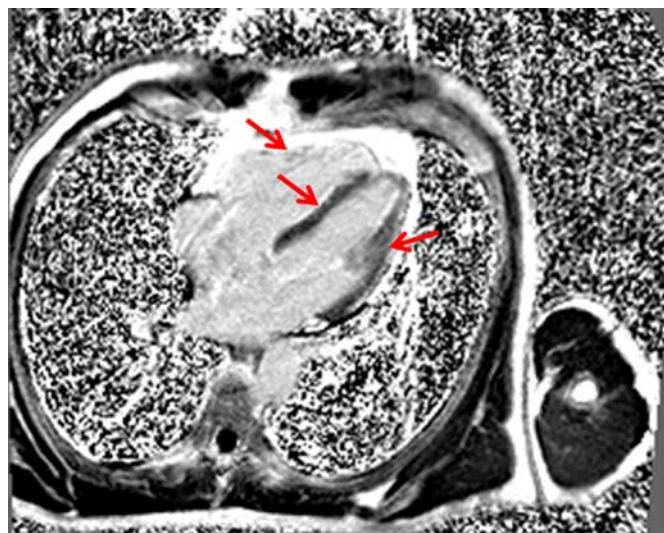


Fig.4. 4 chamber LGE in the right and left ventricles.
LGE – late gadolinium enhancement.

inversion in leads V1-V5 and VT with left bundle-branch block morphology. Genetic counseling assessment was performed for the patient. It was found out that the patient's cousin died suddenly at the age of 40. According to the Task Force 2010 criteria, the diagnosis of ARVC was approved and it was decided to perform genetic test to confirm the molecular diagnosis of the disease.

For SCD prevention and VT suppression extended-release metoprolol was prescribed and implantable cardioverter defibrillator (ICD) was implanted.

After 8 months patient was admitted to emergency room due to VT (heart rate 180 BPM) without ICD discharge. Sinus rhythm was restored by electrical cardioversion (150J) and ICD was reprogrammed. The patient was subsequently treated with Amiodarone.

Next-generation sequencing analysis of genomic DNA isolated from patient's peripheral blood was performed using TruSight Cardio Sequencing panel (Illumina Inc., San Diego, CA). Coding exons of 174 genes were analysed, including the main genes associated with ARVD (*DSC2*, *DSG2*, *DSP*, *JUP*, *PKP2*, *PKP2*, *RYR2*, *TGFB3*, *TMEM43*). A novel likely pathogenic *DSC2* gene (MIM#125645) variant NM_024422.3:c.577_624del, NP_077740.1:p.Gly193_Ser208del, rs767081975 and a variant of uncertain clinical significance in *RYR2* gene (MIM#180902) NM_001035.2:c.9018C>G, NP_001026.2:p.(Ser3006Arg) were identified. The other family members were not available for segregation analysis, since the patient has no children or siblings, his parents died because of cancer and heart failure at the age of 77 and 81. Only the fact of cousin sudden death at the age of 40, which could be associated with congenital heart disease, is known.

Due to thyrotoxicosis, medical treatment with Amiodarone was changed to Metoprolol. Regular yearly follow-ups were planned for the patient.

Discussion

Reasons of palpitations are various, but cardiac disorders are the most common cause of them. Cardiac etiology includes a wide spectrum of heart disorders: arrhythmias caused by acute and chronic ischemia, valvular heart disease, myocarditis, congenital heart diseases [11, 12], and – when the most common cardiac reasons are rejected, rare causes should be suspected – cardiomyopathies and channelopathies such as arrhythmogenic right ventricular cardiomyopathy (ARVC), congenital long QT syndrome (LQTS), catecholaminergic polymorphic ventricular tachycardia (CPVT), left ventricular noncompaction (LVNC), Brugada syndrome (BrS) [4]. All these conditions damage the heart muscle, the scar, fibrosis or fibro-fatty replacement are developed and these facts cause a regional slowing of action potentials, electrical reentry or abnormal automaticity [13]. Palpitations also can occur in the absence of a cardiac arrhythmia because of psychiatric (panic attacks, generalized anxiety disorder, somatization, depression) or miscellaneous causes (drug-induced, thyrotoxicosis, caffeine, cocaine, anemia) [11]. Nevertheless, these diagnoses should not be accepted until arrhythmic etiologies have been excluded. The basic screening of palpitations includes detailed history, physical examination, 12-lead ECG, laboratory testing and sometimes more extensive diagnostic testing for patients at high risk [14]: 24-hour Holter monitoring, exercise ECG testing, dobutamine stress echocardiography, cardiac MRI, coronarography or coronary CT angiography.

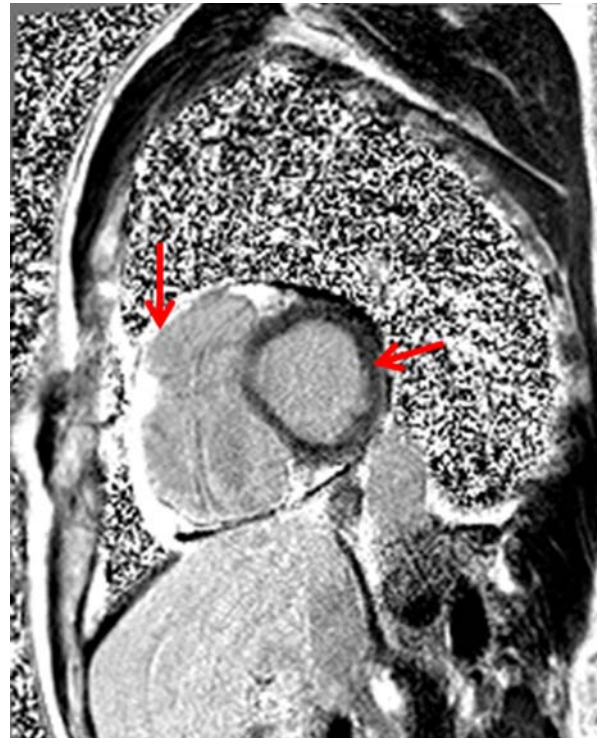

Fig. 5. Short axis LGE in the right and left ventricles. LGE – late gadolinium enhancement

Our patient was complaining of palpitations because of sustained ventricular tachycardia, which repeated several times in a short period. Acute coronary syndrome is the first diagnosis to be ruled out for ventricular arrhythmias. The next step is to reject myocarditis, heart failure and cardiomyopathies. Inverted T waves in precordial leads (V1-5) and the presence of complete right bundle-branch block in ECG suggested to look for right ventricular abnormalities. According to this fact, investigation of patient was extensive and involved imaging tests. The cause of ventricular arrhythmia was suspected when transthoracic echocardiogram and diagnosed when cardiac magnetic resonance was performed.

The patient was older than the mean age at diagnosis for the most congenital heart disease (65-year-old), therefore this fact misled from suspecting genetic disorder during the first hospitalization. However, the characteristic features of ARVC allowed thinking about this disease later. Clinical manifestation of ARVC is the most common in approximately 30 years of age, however it varies between the age of 10 and 50 years [15–18]. Mean age at diagnosis of other congenital cardiomyopathies and channelopathies also varies, but typically they manifest until 40 years [4].

Several diagnostic tests are needed to evaluate diagnosis of ARVC. According to recommendations, basic screening includes family history, 12-lead ECG, transthoracic echocardiography and cardiac MRI in all patients with a suspected diagnosis of ARVC [14]. Echocardiographic criteria include evaluation of regional RV akinesia, dyskinesia or aneurysm, measures of RVOT enlargement and reduction in RV fractional area changed (FAC). MRI is recommended to all patients with suspected ARVC, because it plays the most important role in identification of global and regional ventricular dilatation or dysfunction, late gadolinium enhancement, focal wall thinning, intramyocardial fat. These two tools were the most important in detecting etiology of ARVC cardiac episode in the described case.

ARVC diagnosis is based on diagnostic criteria, which were initially proposed by an international Task Force [McKenna et al 1994] [19], and were revised by Marcus et al [2010] [2]. Individuals are classified as having a definite, borderline, or possible diagnosis of ARVC based on the number of major and/or minor diagnostic criteria presented in 6 categories, including global or regional dysfunction and structural alterations, tissue characterization of wall, repolarization abnormalities, depolarization/conduction abnormalities, arrhythmias, and family history. Definite diagnosis of ARVC using the 2010 revised Task Force Criteria requires the presence of 2 major criteria or 1 major and 2 minor criteria or 4 minor criteria from different categories [2, 19]. Our patient has met 1 major and 2 minor criteria from three different categories for the definite diagnosis of ARVC [2, 19]. Additionally, identification of a likely pathogenic variant in *DSC2* gene gives additional major criterion and, in overall, our described patient has met 2 major and 2 minor criteria from four different categories.

Genetic testing is important for familial cases and allows to estimate the risk for first-degree relatives, thus genetic counseling is strongly advised for family members of the proband with ARVC-causative mutation [4]. Data from literature suggest that 30 percent of cases of ARVC are familial [20–23]. *DSC2* gene alterations are identified in 2 to 7 percent of ARVC [4]. *DSC2* gene is found in a cluster with other desmocollin family members. Desmocollins, along with desmogleins, are cadherin-like transmembrane glycoproteins that are major components of the desmosomes which lead cells adhesion and are found in cells subject to mechanical stress.

Despite the identification of the two novel variants in ARVC-associated genes, the assessment of their pathogenicity was not very straightforward. The variant c.577_624del, detected in our patient in *DSC2* gene has not been reported previously as pathogenic or as a benign polymorphism, to our knowledge. According to *in silico* analysis of pathogenicity, Mutation Taster algorithm predicted the identified c.577_624del variant as disease causing (0,99). The variant results in the non-frameshift deletion of 16 amino acids in the Cadherin domain of the *DSC2* protein p.(Gly193_Ser208del) [24]. Missense variants that are located within the genomic region deleted in our patient (p.Asn194Lys,

p.Arg203His, p. Arg203Cys) have been reported in the Human GeneMutation Database in association with ARVC [27-29], supporting the functional importance of this region of the protein. However, the ClinVar database classified (and does it so far) the variant as VUS making the evaluation of the variant slightly complicated. Still, according to ACMG criteria the inframe deletion scored at least 3 moderate and 1 supporting criteria of pathogenicity allowing us to attribute it to likely pathogenic class of variants. Nevertheless, a functional test would be required to confirm the pathogenicity of this alteration.

The evaluation of the contribution of the c.9018C>G variant in *RYR2* gene to the clinical features of our patient was also difficult. Cardiac ryanodine receptor (*RYR2*) gene mediates the release of diastolic calcium from the sarcoplasmic reticulum that is required for myocardial contraction. Changes in this gene can trigger life-threatening ventricular arrhythmias and sudden cardiac death [25]. Mutations of *RYR2* are characteristic for patients with catecholaminergic polymorphic ventricular tachycardia – up to 60 percent of cases are related to this gene mutation [4]. The variant c.9018C>G detected in our patient was not described in the 1000 Genomes Project or ExAC database, what indicates it is not a common benign variant in these populations. However, this variant and any other variants in close positions have not been reported in the literature in individuals related with ARVC, and the predictions of pathogenicity using *in silico* tools are conflicting. Although the variant is extremely rare it is expected to change amino acid in functionally less active C terminus of the protein which does not belong to any domain of ryanodine receptor 2. Therefore, according to ACMG criteria we decided to classify the missense variant of *RYR2* gene as VUS (variant of unknown significance).

The main dangers of ARVC are the progression of the ventricular arrhythmias that cause SCD and the development of heart failure [26]. For these reasons, there are several key goals for the treatment of the disease [26]: reduction of mortality, limiting progression and symptoms of the disease, improvement of life quality. ARVC treatment also includes lifestyle changes, pharmacological treatment, catheter ablation, ICD implantation and heart transplantation, which are suggested for individuals with advanced end-stage heart failure or in case of uncontrolled ventricular tachycardia. The main tool for preventing SCD is the implantable cardioverter defibrillator (ICD). Our described patient was stratified as having high risk for major arrhythmic events [26], he had strong indication to implant ICD for SCD prevention [14, 26].

Limitations

A major limit of this case report is the fact that there was no possibility to perform segregation analysis for the other family members of patient, because he has no children or siblings, his parents are dead. Extensive familial genetic testing could let to assess the pathogenicity of the two novel identified variants in ARVC-associated genes and to classify their clinical significance.

Conclusion

Diagnostic evaluation of ARVC is challenging and requires multidisciplinary team collaboration. ECG, transthoracic echocardiogram and cardiac magnetic resonance imaging are very important for ventricular arrhythmias differential diagnosis. Subsequently performed genetic testing led to the identification of a novel ARVC likely pathogenic variant *in DSC2* gene and variant of uncertain significance in *RYR2* gene. Further functional tests for elucidation of the clinical significance of the variants could be suggested.

Conflict of interest

The authors declare no conflict of interest.

References

1. Haugaa KH, Haland TF, Leren IS, Saberniak J, Edvardsen T. Arrhythmogenic right ventricular cardiomyopathy, clinical manifestations, and diagnosis. *EP Eur*. 2016 Jul 1;18(7):965–72. DOI: 10.1093/europace/euv340
2. Marcus FI, McKenna WJ, Sherrill D, Basso C, Bauce B, Bluemke DA, et al. Diagnosis of Arrhythmogenic Right Ventricular Cardiomyopathy/Dysplasia: Proposed Modification of the Task Force Criteria. *Circulation*. 2010 Apr 6;121(13):1533–41. DOI: 10.1093/eurheartj/ehq025
3. Corrado D, Basso C, Schiavon M, Thiene G. Screening for Hypertrophic Cardiomyopathy in Young Athletes. *N Engl J Med*. 1998 Aug 6;339(6):364–9. DOI: 10.1056/NEJM199808063390602
4. Ackerman MJ, Priori SG, Willems S, Berul C, Brugada R, Calkins H, et al. HRS/EHRA Expert Consensus Statement on the State of Genetic Testing for the Channelopathies and Cardiomyopathies This document was developed as a partnership between the Heart Rhythm Society (HRS) and the European Heart Rhythm Association (EHRA). *EP Eur*. 2011 Aug 1;13(8):1077–109. DOI: 10.1016/j.hrthm.2011.05.020
5. Hall CL, Sutanto H, Dalageorgou C, McKenna WJ, Syrris P, Futema M. Frequency of genetic variants associated with arrhythmogenic right ventricular cardiomyopathy in the genome aggregation database. *Eur J Hum Genet*. 2018 Sep;26(9):1312. <https://doi.org/10.1038/s41431-018-0169-4>
6. Que D, Yang P, Song X, Liu L. Traditional vs. genetic pathogenesis of arrhythmogenic right ventricular cardiomyopathy. *EP Eur*. 2015 Dec 1;17(12):1770–6. DOI: 10.1093/europace/euv042
7. Sen-Chowdhry S, Syrris P, McKenna WJ. Genetics of right ventricular cardiomyopathy. *J Cardiovasc Electro-physiol*. 2005 Aug;16(8):927–35. DOI: 10.1111/j.1540-8167.2005.40842.x
8. Pelliccia A, Corrado D, Bjørnstad HH, Panhuyzen-Goedkoop N, Urhausen A, Carre F, et al. Recommendations for participation in competitive sport and leisure-time physical activity in individuals with cardiomyopathies, myocarditis and pericarditis. *Eur J Cardiovasc Prev Rehabil*. 2006 Dec;13(6):876–85. DOI: 10.1097/01.hjr.0000238393.96975.32
9. Kirchhof P, Fabritz L, Zwiener M, Witt H, Schäfers M, Zellerhoff S, et al. Age- and Training-Dependent Development of Arrhythmogenic Right Ventricular Cardiomyopathy in Heterozygous Plakoglobin-Deficient Mice. *Circulation*. 2006 Oct 24;114(17):1799–806. DOI: 10.1161/CIRCULATIONAHA.106.624502
10. McNally E, MacLeod H, Dellefave-Castillo L. Arrhythmogenic Right Ventricular Cardiomyopathy. In: Adam MP, Ardinger HH, Pagon RA, Wallace SE, Bean LJ, Stephens K, et al., editors. *GeneReviews*® [Internet]. Seattle (WA): University of Washington, Seattle; 1993 [cited 2019 Feb 16]. Available from: <http://www.ncbi.nlm.nih.gov/books/NBK1131/>
11. Weber BE, Kapoor WN. Evaluation and outcomes of patients with palpitations. *Am J Med*. 1996 Feb;100(2):138–48. DOI: 10.1016/s0002-9343(97)89451-x
12. Dr. Paul Khairy, Adult Congenital Heart Center, Montreal Heart Institute, 5000 Belanger St. E., Montreal, QC, Canada. *Cardiac Arrhythmias In Congenital Heart Diseases* [Internet]. [cited 2019 May 4]. Available from: <https://www.ncbi.nlm.nih.gov/pmc/articles/PMC2766579/>
13. Steven J Compton, MD, FACC, FACP, FHRS. *Ventricular Tachycardia: Practice Essentials, Background, Pathophysiology* [Internet]. [cited 2019 May 4]. Available from: <https://emedicine.medscape.com/article/159075-overview>
14. Priori SG, Blomström-Lundqvist C, Mazzanti A, Blom N, Borggrefe M, Camm J, et al. 2015 ESC Guidelines for the management of patients with ventricular arrhythmias and the prevention of sudden cardiac death The Task Force for the Management of Patients with Ventricular Arrhythmias and the Prevention of Sudden Cardiac Death of the European Society of Cardiology (ESC) Endorsed by: Association for European Paediatric and Congenital Cardiology (AEPCC). *Eur Heart J*. 2015 Nov 1;36(41):2793–867. DOI: 10.1093/eurheartj/ehv316
15. Groeneweg JA, Bhonsale A, James CA, te Riele AS, Dooijes D, Tichnell C, et al. Clinical Presentation, Long-Term Follow-Up, and Outcomes of 1001 Arrhythmogenic Right Ventricular Dysplasia/Cardiomyopathy Patients and Family Members. *Circ Cardiovasc Genet*. 2015 Jun;8(3):437–46. DOI: 10.1161/CIRCGENETICS.114.001003
16. Dalal D, Nasir K, Bomma C, Prakasa K, Tandri H, Piccini J, et al. Arrhythmogenic right ventricular dysplasia: a United States experience. *Circulation*. 2005 Dec 20;112(25):3823–32. DOI: 10.1161/CIRCULATIONAHA.105.542266
17. Nava A, Bauce B, Basso C, Muriago M, Rampazzo A, Villanova C, et al. Clinical profile and long-term follow-up of 37 families with arrhythmogenic right ventricular cardiomyopathy. *J Am Coll Cardiol*. 2000 Dec;36(7):2226–33. DOI: 10.1016/s0735-1097(00)00997-9

18. Hulot J-S, Jouven X, Empana J-P, Frank R, Fontaine G. Natural History and Risk Stratification of Arrhythmogenic Right Ventricular Dysplasia/Cardiomyopathy. *Circulation*. 2004 Oct 5;110(14):1879–84. DOI: 10.1161/01.CIR.0000143375.93288.82
19. McKenna WJ, Thiene G, Nava A, Fontaliran F, Blomstrom-Lundqvist C, Fontaine G, et al. Diagnosis of arrhythmogenic right ventricular dysplasia/cardiomyopathy. Task Force of the Working Group Myocardial and Pericardial Disease of the European Society of Cardiology and of the Scientific Council on Cardiomyopathies of the International Society and Federation of Cardiology. *Heart*. 1994 Mar 1;71(3):215–8. DOI: 10.1136/hrt.71.3.215
20. Hermida JS, Minassian A, Jarry G, Delonca J, Rey JL, Quiret JC, et al. Familial incidence of late ventricular potentials and electrocardiographic abnormalities in arrhythmogenic right ventricular dysplasia. *Am J Cardiol*. 1997 May 15;79(10):1375–80. DOI: 10.1016/s0002-9149(97)00143-4
21. Bhonsale A, Groeneweg JA, James CA, Dooijes D, Tichnell C, Jongbloed JDH, et al. Impact of genotype on clinical course in arrhythmogenic right ventricular dysplasia/cardiomyopathy-associated mutation carriers. *Eur Heart J*. 2015 Apr 7;36(14):847–55. DOI: 10.1093/eurheartj/ehu509
22. Corrado D, Link MS, Calkins H. Arrhythmogenic Right Ventricular Cardiomyopathy. *N Engl J Med*. 2017 Jan 5;376(1):61–72. DOI: 10.1056/NEJMra1509267
23. Mutation in Human Desmoplakin Domain Binding to Plakoglobin Causes a Dominant Form of Arrhythmogenic Right Ventricular Cardiomyopathy: The American Journal of Human Genetics [Internet]. [cited 2018 Feb 20]. Available from: [http://www.cell.com/ajhg/fulltext/S0002-9297\(07\)60414-5](http://www.cell.com/ajhg/fulltext/S0002-9297(07)60414-5)
24. NM_024422.4(DSC2):c.577_624del (p.Gly193_Ser208del) Simple - Variation Report - ClinVar - NCBI [Internet]. [cited 2019 Feb 18]. Available from: <https://www.ncbi.nlm.nih.gov/clinvar/variation/536275/#summary-evidence>
25. Wehrens XHT, Lehnart SE, Huang F, Vest JA, Reiken SR, Mohler PJ, et al. FKBP12.6 Deficiency and Defective Calcium Release Channel (Ryanodine Receptor) Function Linked to Exercise-Induced Sudden Cardiac Death. *Cell*. 2003 Jun 27;113(7):829–40. DOI: 10.1016/s0092-8674(03)00434-3
26. Corrado D, Wichter T, Link MS, Hauer R, Marchlinski F, Anastasakis A, et al. Treatment of arrhythmogenic right ventricular cardiomyopathy/dysplasia: an international task force consensus statement. *Eur Heart J*. 2015 Dec 7;36(46):3227–37. DOI: 10.1161/CIRCULATIONAHA.115.017944
27. Ohno S, Nagaoka I, Fukuyama M, Kimura H, Itoh H, Makiyama T, Shimizu A, Horie M. Age-dependent clinical and genetic characteristics in Japanese patients with arrhythmogenic right ventricular cardiomyopathy/dysplasia. *Circ J*. 2013;77(6):1534–42. Epub 2013 Mar 20. <https://doi.org/10.1253/circj.CJ-12-1446>
28. Kapplinger JD, Landstrom AP, Salisbury BA, Callis TE, Pollevick GD, Tester DJ, Cox MG, Bhuiyan Z, Bikker H, Wiesfeld AC, Hauer RN, van Tintelen JP, Jongbloed JD, Calkins H, Judge DP, Wilde AA, Ackerman MJ. Distinguishing arrhythmogenic right ventricular cardiomyopathy/dysplasia-associated mutations from background genetic noise. *J Am Coll Cardiol*. 2011 Jun 7;57(23):2317–27. DOI: 10.1016/j.jacc.2010.12.036
29. Gehmlich K, Syrris P, Peskett E, Evans A, Ehler E, Asimaki A, Anastasakis A, Tsatsopoulou A, Vouliotis AI, Stefanadis C, Saffitz JE, Protonotarios N, McKenna WJ. Mechanistic insights into arrhythmogenic right ventricular cardiomyopathy caused by desmocollin-2 mutations. *Cardiovasc Res*. 2011 Apr 1;90(1):77–87. DOI: 10.1093/cvr/cvq353