

Imaging in pregnancy-associated breast cancer: a case report

Audrius Untanas^{1*},

Indrė Grigaitė¹,

Rūta Briedienė^{1,2}

¹Faculty of Medicine,
Vilnius University,
Vilnius, Lithuania

²National Cancer Institute,
Vilnius, Lithuania

Background. PABC (pregnancy-associated breast cancer) is a rare condition that appears as a malignancy in 1 per 3000 pregnant women and is one of the most common cancers diagnosed during pregnancy or the postpartum period. If a woman who is pregnant or within a year after delivery has complaints of a palpable breast mass, it could undeniably be a malignant mass of the breast. That is why an ultrasound should be performed for all pregnant or lactating women who detect a palpable breast mass that persists for two or more weeks.

Case report. Our case report presents a pregnant 40-year-old previously healthy female at 36 weeks gestational age with a complaint of a palpable left breast mass for two months period. The initial ultrasound showed a breast tumour of irregular shape, solid and hypervascular mass.

Conclusions. Early diagnostics of PABC is of crucial importance in order to offer the best possible outcomes for the patient and foetus.

Keywords: PABC, breast cancer, pregnancy, ultrasound, magnetic resonance

BACKGROUND

Pregnancy-associated breast cancer (PABC) is determined as a breast malignancy identified for women during pregnancy or within the first twelve postpartum months (1, 2).

Some evidence suggests that it is worthwhile to differentiate between diagnosis during pregnancy and diagnosis during the postpartum phase (18) because separating patients in this way reveals a potential prognostic difference between the two groups. Women with PABC have not been

shown to have a poorer prognosis than non-pregnant women with breast cancer after matching for the stage, age, and the year of diagnosis, whereas patients with breast cancer diagnosed during the postpartum period may have a worse prognosis than women with non-PABC when matched for such prognostic factors (19). The diagnostic possibilities also vary in these groups of patients because of the wide spectrum of diagnostic methods in postpartum women and the strict contraindications for X-ray-based or contrast-enhanced studies in pregnant women.

PABC is a rare condition that appears as a malignancy in 1 per 3000 pregnant women and is one of the most common cancers diagnosed during

* Correspondence to: Audrius Untanas, Faculty of Medicine, Vilnius University, M. K. Čiurlionio St. 21, Vilnius 03101, Lithuania. Email: audrius.untanas@gmail.com

pregnancy or the postpartum period (2). However, when a breast malignancy is diagnosed around the age of 23 to 47, more than 3% of the cases are associated with pregnancy (2). Moreover, the possibility that PABC will be detected increases from 10% to 20% (3) for women that are below 30 years of age and when it appears, most of the time it is associated with a high risk of death (2). The incidence of pregnancy-associated breast cancer (PABC) increases as more women choose to delay childbearing and the population-based incidence of breast cancer rises.

According to the literature review, the majority of PABC cases histopathological and immunohistochemical features are high-grade invasive ductal carcinoma, which is oestrogen receptor-negative and progesterone receptor-negative (4). Some studies indicate that HER-2/neu expression is suppressed in breast cancers during pregnancy or lactation and tumours that occurred after delivery or cessation of lactation were positive (5).

Because of it, it is extremely significant to choose the most accurate imaging technique for detecting PABC in early stages to achieve the best treatment outcomes for the patient.

Case report

A 40-year-old previously healthy female, at 36 weeks gestational age arrived at the National Cancer Institute complaining of left breast mass pal-

pable for as long as two months. A Caesarean section was performed six years ago. She had neither personal nor family history of cancer and was not treated for chronic diseases. The patient also denied any use of alcohol or cigarettes.

Physical examination revealed a firm approximately 11 cm-size left breast mass in the upper outer quadrant with associated skin erythema and palpable left axillary lymph nodes.

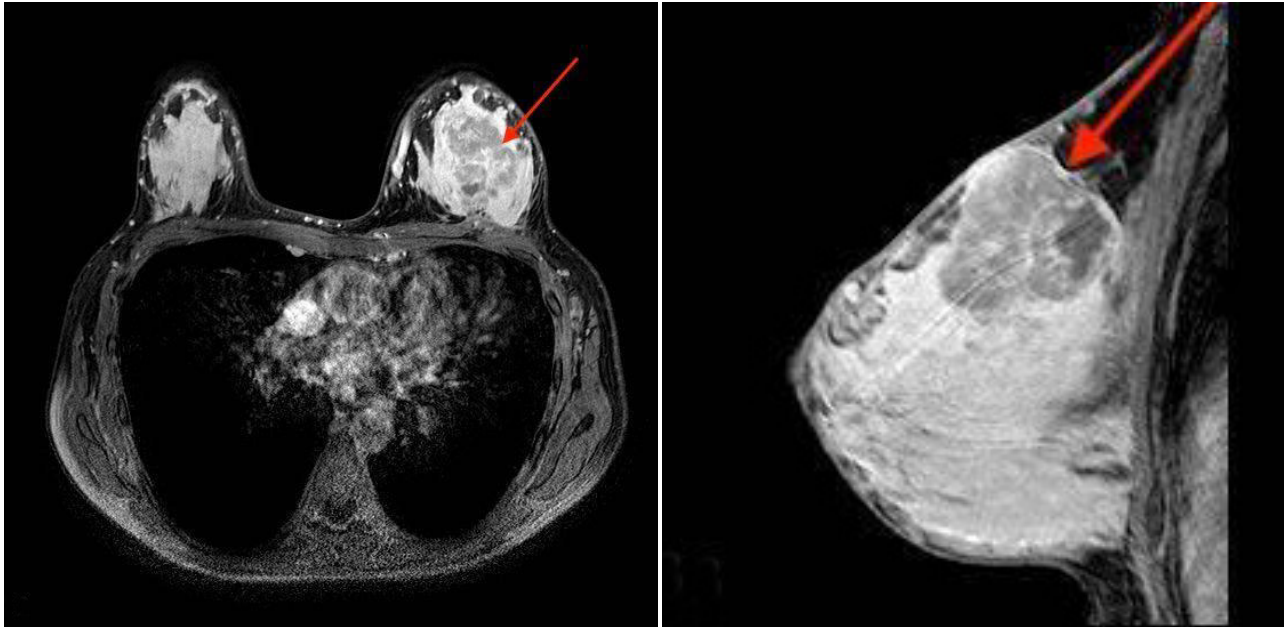
The initial ultrasound (Fig. 1) showed a breast tumour of an irregular shape, a solid and hypervascular mass measuring 6 × 5 cm. All the findings were highly suspicious for malignancy and were score 5 according to the Breast Imaging, Reporting and Data System (BI-RADS).

Based on the results of palpation and breast ultrasound, a left breast biopsy and histological analysis were performed to identify the type of the mass. The histological examination showed oestrogen receptor-positive, progesterone receptor-negative, androgen receptor-negative, and human epidermal growth factor receptor 2 (HER2) negative invasive poorly differentiated (Grade 3) ductal carcinoma.

After a multidisciplinary case conference, it was decided to delay further radiological diagnostics until the delivery of the newborn at 37 weeks of gestation. After Caesarean section, breast magnetic resonance imaging (Figs. 2 and 3) and computed tomography (Fig. 4) were performed. On

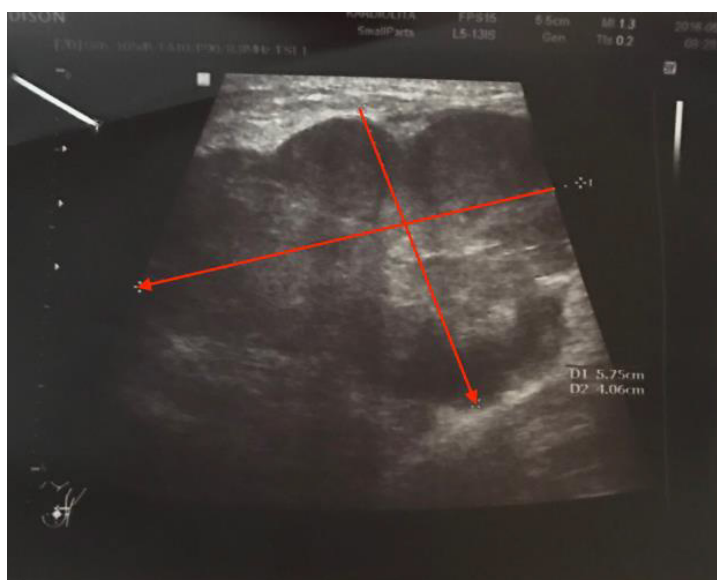

Fig. 1. An irregular-shaped tumour visible on ultrasound in the left breast



Figs. 2 and 3. Breast MRI shows extremely dense enhanced glandular tissue with abnormal irregular-shaped tumour in the left breast

MRI, an extremely dense glandular tissue with abnormal enhancement measuring $5 \times 5 \times 4.6$ cm, of irregular shape and irregular margins was found, leading to score 5 in the BI-RADS classification. CT scan was done because of disease distant staging. It showed a 47×42 mm left breast mass with liquid density areas. Also, the involvement of axillary lymph nodes on the left side was noted, no signs of distant metastatic disease were found.

The patient received chemotherapy consisting of weekly paclitaxel and followed by adriamycin and cyclophosphamide. Signs of the breast mass destruction were recorded after two weeks of the treatment, which lead to the left modified radical mastectomy. Surgery was uneventful and the final report of the histology revealed invasive poorly differentiated G3 ductal carcinoma ypT3 (58 mm) stage pT3N3M0. After a surgical treatment, the patient

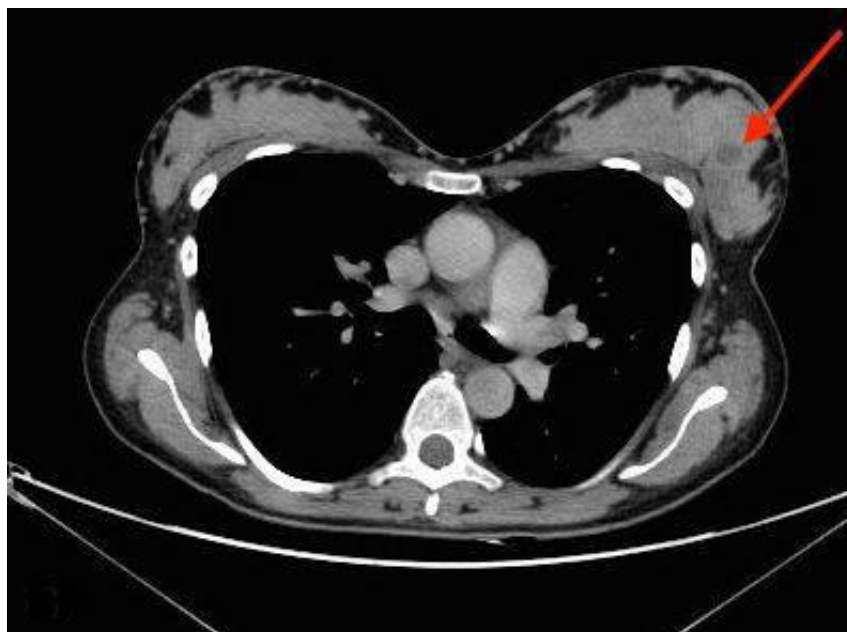

Fig. 4. On CT scan, a left breast mass with liquid density areas were visible

underwent chemotherapy (consisting of paclitaxel for 12 weeks), hormonal therapy (tamoxifen), and radiation therapy given.

Six months after the radiation therapy, a CT scan showed axillary involvement of lymph nodes on the left side, which was confirmed by the histological examination. The patient received chemotherapy (consisting of docetaxel). She also underwent the Breast Cancer antigen (BRCA) I and II gene testing and it did not display any pathological mutations in the gene. A bilateral adnexectomy was performed due to the woman's age, her hormonal changes, and disease aggressiveness. No complications were reported to the patient or her baby during this period of time.

DISCUSSION

In the majority of cases, when a woman notices a palpable mass in her breast during pregnancy or postpartum, it can be caused by lobular hyperplasia, lactation calcifications, or lactation adenoma triggered by physiological changes (6). However, when a woman complains of a palpable breast mass, the malignancy of the palpable breast mass can never be eliminated.

An ultrasound is the main radiological examination for a pregnant or lactating woman with a palpable breast mass (7). The most important thing in detecting a PABC is to locate a suspicious palpable breast mass and adjust high-sensitivity with a minimum harm to foetus (7). An ultrasound should be performed for all pregnant or lactating women who detect a palpable breast mass persisting for two or more weeks (8). Expedience of ultrasound in clarifying malignancy of a breast mass is well explained in the studies that reported 99% sensitivity and 99% negative predictive value for detecting PABC (6, 9). Also, an ultrasound is the best diagnostic instrument for evaluating breast malignancies of the PABC type or for patients who are below 30 years of age (10). Over 80% of breast masses identified in pregnancy represent benign pathologies. Aetiologies include lobular hyperplasia, fibroadenoma, cystic disease, galactocele, abscess, and lipoma. Nonetheless, each mass needs to be thoroughly evaluated (20). In our case, ultrasound was performed immediately after the palpable mass was found.

In some cases imaging lesions with ultrasound are inconspicuous, which can lead to the use of

mammography (11) while the risks and the benefits for a patient and foetus should be estimated (12). First of all, the patient should be warned of the risks of ionizing radiation to the foetus and then all the advantages of this examination method should be explained. To minimise the risk during mammography, an abdominal shielding should be used, which decreases ionizing radiation for the patient and the foetus from 0.03 Gy to 0.004 Gy (7, 12). However, mammography should only be performed for detecting PABC when it is really necessary or when the results of ultrasound are questionable (9). An ultrasound evaluation is approximately 12% more accurate and sensitive than mammography, because physiologically breast parenchyma is influenced by hormonal changes during pregnancy and the lactating period (7, 10). Mammography is recommended to reject or to approve malignancy of a mass in a breast if ultrasound examination shows a highly suspicious mass, palpable during examination. An ultrasound examination cannot identify if a mass is truly malignant or if there are any suspicious micro-calcifications (7, 13).

MRI is used mostly to detect breast malignancy in non-pregnant women. The European Society of Urogenital Radiology has released guidelines, according to which there are no proven studies of the toxic impact of gadolinium on the foetus (15). Unfortunately, there are no proven studies of gadolinium non-toxic impact on foetus either, so gadolinium-enhanced MRI is contraindicated for pregnant women, because gadolinium may cross the placenta and no one knows how it can affect the foetus (14). Consequently, MRI as a diagnostic method is not recommended for the evaluation of PABC during pregnancy and it can be performed in rare situations when benefits of this method are greater than the danger to the foetus (14). Also, it is not possible to perform a breast MRI on a pregnant patient because of the face-down position that is required for a breast MRI. Most of the pregnant women are not capable to lie down on their abdomen. A breast MRI with gadolinium contrast can be performed safely when the patient with PABC is lactating, but it is contraindicated to breastfeed a baby for 24 hours after the breast MRI (16, 17). In our case, further diagnostic tests, including a breast MRI, were performed after the delivery of a newborn at 37 weeks of gestation, to identify the type of the tumour.

Many women with breast cancer during pregnancy are in advanced stages at the time of diagnosis and a thorough evaluation of possible metastasis is warranted. Breast cancer most commonly metastasizes to the lungs, the liver, and bones. With appropriate abdominal shielding, chest radiographs are considered safe during pregnancy, to evaluate any lung metastasis. Liver metastases can be evaluated with ultrasound. Outside of pregnancy, evaluation of bone metastasis is usually accomplished with a bone scan; however, in pregnancy the radioactive technetium can be harmful to the rapidly developing foetal skeleton. Therefore, evaluation for bone metastasis in pregnancy can be done with noncontrast magnetic resonance imaging (21, 22).

Because breast cancer in pregnancy is usually diagnosed with delay and patients feel and detect it themselves as a palpable mass, there is a need for guidelines and systematic screening of all pregnant patients. The Society of Obstetricians and Gynaecologists of Canada published guidelines on breast cancer and pregnancy, which focus mainly on the treatment and management of the disease. Recommendations from an expert meeting on breast cancer during pregnancy advise systematically screening all pregnant patients with a breast examination during the first prenatal visit or early in the pregnancy. There is a dedicated section for breast examination on the prenatal forms used by all obstetricians for new patients in Quebec. Despite these guidelines, however, there are no measures for determining whether routine breast examinations are done in obstetrical patients, and there is no evidence to show that there has been an improvement in diagnostic delay (19).

CONCLUSIONS

When a patient with a palpable breast mass persisting for two weeks (or more) is presented, one of the most important tasks for the radiologists is to avoid a delay in PABC diagnostics. Firstly, an ultrasound should be performed during radiological examination for all pregnant or lactating patients with a palpable breast mass. Other methods of instrumental examination, such as mammography or MRI, require strict indications when results of ultrasound are uncertain to identify a PABC. In other cases mammography and MRI should be performed after the delivery, to avoid any risk to the foetus. For

distant spread of the disease, a whole body MRI and ultrasound could be an option in pregnant patients and a whole body CT, PET, or other methods are available for post-partum patients. Because PABC is usually detected with delay in diagnosis, there is a need for guidelines and systematic screening of all pregnant patients.

Received 25 March 2019

Accepted 4 June 2019

References

1. Myers KS, Green LA, Lebron L, Morris EA. Imaging appearance and clinical impact of preoperative breast MRI in pregnancy-associated breast cancer. *AJR*. 2017; 209: 177–83.
2. Navrozoglou I, Vrekoussis T, Kontostolis E, Doucias V, Zervoudis S, Stathopoulos EN, Zoras O, Paraskevaidis E. Breast cancer during pregnancy: a mini-review. *Eur J Surg Oncol*. 2008; 34(8): 837–43.
3. Litton JK, Theriault RL, Gonzalez-Angulo AM. Breast cancer diagnosis during pregnancy. *Women's Health (London, England)*. 2009; 5(3): 243–9.
4. Middleton LP, Amin M, Gwyn K, Theriault R, Sahin A. Breast carcinoma in pregnant women: assessment of clinicopathologic and immunohistochemical features. *Cancer*. 2003; 98: 1055–60.
5. Shousha S. Breast carcinoma presenting during or shortly after pregnancy and lactation. *Arch Pathol Lab Med*. 2000; 124: 1053–60.
6. Joshi S, Dialani V, Marotti J, S. Mehta T, Slanetz PJ. Breast disease in the pregnant and lactating patient: radiological-pathological correlation. *Insights Imaging*. 2013 Oct; 4(5): 527–38.
7. Vashi R, Hooley R, Butler R, Geisel J, Philpotts L. Breast imaging of the pregnant and lactating patient: imaging modalities and pregnancy-associated breast cancer. *AJ R*. 2013; 200: 321–8.
8. Woo JC, Yu T, Hurd TC. Breast cancer in pregnancy: a literature review. *Arch Surg*. 2003; 138: 91–8.
9. Ahn BY, Kim HH, Moon WK. Pregnancy and lactation-associated breast cancer: mammographic and sonographic findings. *J Ultrasound Med*. 2003; 22: 491–7.
10. Robbins J, Jeffries D, Roubidoux M, Halvie M. accuracy of diagnostic mammography and breast ultrasound during pregnancy and lactation. *AJ R*. 2011; 196: 716–22.

11. National Comprehensive Cancer Network. Clinical practice guidelines in oncology: breast cancer screening and diagnosis guidelines. Vol. 1. Fort Washington: National Comprehensive Cancer Network, 2008.
12. Ring AE, Smith IE, Ellis PA. Breast cancer and pregnancy: Review. *Ann Oncol.* 2005; 10: 1855–60.
13. Yang WT, Dryden MJ, Gwyn K, Whitman GJ, Theriault R. Imaging of breast cancer diagnosed and treated with chemotherapy during pregnancy. *Radiology.* 2006; 239: 52–60.
14. Ayyappan AP, Kulkarni S, Crystal P. Pregnancy-associated breast cancer: spectrum of imaging appearances. *Br J Radiol.* 2010; 83: 529–34.
15. Webb JA, Thomsen HS, Morcos SK. Members of Contrast Media Safety Committee of European Society of Urogenital Radiology (ESUR). The use of iodinated and gadolinium contrast media during pregnancy and lactation. *Eur Radiol.* 2005; 15: 1234–40.
16. American College of Radiology website. ACR manual on contrast media. www.acr.org/~media/ACR/Documents/PDF/QualitySafety/Resources/Contrast%20Manual/FullManual.pdf. Published 2010. [cited 2012 Sept 26].
17. Talele AC, Slanetz PJ, Edmister WB, Yeh ED, Kopans DB. The lactating breast: MRI findings and literature review. *Breast J.* 2003; 9: 237–240 16.
18. Lyons TR, Schedin PJ, Borges VF. Pregnancy and breast cancer: when they collide. *J Mammary Gland Biol Neoplasia.* 2009; 14: 87–98.
19. Buré LA, BSc, Azoulay L, Benjamin A, Abenhaim HA. Pregnancy-Associated Breast Cancer: A Review for the Obstetrical Care Provider. *JOGC.* 2011; 330–7.
20. Theriault R, Hahn K. Management of breast cancer in pregnancy. *Curr Oncol Rep.* 2007; 9(1): 17–21.
21. Molckovsky A, Madarnas Y. Breast cancer in pregnancy: a literature review. *Breast Cancer Res Treat.* 2008; 108: 333–8.
22. Keyser EA, Staat BC, Fausett MB, Shields AD. Pregnancy-associated breast cancer. *Rev Obstet Gynecol.* 2012; 5(2): 94–9.

Audrius Untanas, Indrė Grigaitė, Rūta Briedienė

SU NĖŠTUMU SUSIJUSIO KRŪTIES VĖŽIO RADIOLIGINIS VAIZDINIMAS: ATVEJO PRISTATYMAS

Santrauka

Apžvalga. Krūties vėžys nėštumo metu – reta būklė, pasitaikanti 1 iš 3 000 nėščiųjų. Krūties vėžys yra dažniausias nėščiųjų ir maitinančiųjų moterų vėžinis susirgimas. Jei pacientė nėštumo periodu atvyksta sučiuopiamu dariniu krūtų srityje, piktybinės kilmės naviko tikimybė negali būti atmesta. Dėl šios priežasties visoms nėščiosioms ir maitinančioms moterims, kurių krūtyse palpuojamas darinys išlieka dvi ar daugiau savaičių, privaloma atlikti krūtų ultragarso tyrimą darinio kilmei diferencijuoti.

Klinikinis atvejis. Analizuojamas klinikinis atvejis, kai keturiasdešimties metų moteris 36-tą nėštumo savaitę atvyko į gydymo įstaigą planinei gydytojo konsultacijai bei išsamiam klinikiniam ištyrimui dėl kairėje krūtyje palpuojamo kieto darinio, kurį pirmą kartą apčiuopė prieš du mėnesius. Įvertinus pacientės būklę ir atlikus krūtų ultragarso tyrimą, stebėtas maždaug 5 cm dydžio, neaiškių ribų, vientisas su kapiliariniu tinklu navikas kairėje krūtyje. Visi ultragarso tyrimo aptikti naviko patologiniai morfologiniai radiniai įvertinti penkais balais pagal BI-RADS sistemą.

Išvados. Analizuotas klinikinis atvejis parodo nėščiųjų krūtų navikų ankstyvos diagnostikos svarbą siekiant geriausio gydymo tiek pacientei, tiek vaisiui.

Raktažodžiai: krūties vėžys, nėštumas, ultragarso, magnetinis rezonansas